

## Effects of two suture methods under arthroscopy on isolated occult medial meniscocapsular separation

Wenhu Li; Zhengbo Hu\*; Penghuan Wu; Zhinian Zhong; Xiao Wei\*

**\*Corresponding Author: Zhengbo Hu & Xiao Wei**

Department of Orthopaedics, Shaoguan First People's Hospital, Shao Guan Hospital Southern Medical University, Guangdong, 512000, China.

Email: 592008795@qq.com; 407822759@qq.com

### Abstract

**Background:** This study aimed to describe and analyze the clinical efficacy of two suture methods for treating isolated occult medial meniscocapsular separation (IOMMCS).

**Methods:** The clinical data of 67 IOMMCS patients from January 2017 to January 2020 were retrospectively analyzed, including 47 males and 20 females, with an average age of 41 years (range: 21-67 years). IOMMCS was diagnosed by arthroscopy. The control group was treated with direct sutures after routine endoscopic freshness, and the observation group was treated with latent sutures after PRP injection filling. The VAS score of resting pain, subjective WOMAC score of knee joint, objective Lysholm score, and postoperative complications were compared between the two groups at different times before and after the operation.

**Results:** The two groups were followed up for an average of 31 months, and the complete remission of postoperative symptoms represented the last follow-up. Before and after the operation, the VAS, WOMAC, and Lysholm scores significantly improved in the observation and control groups, and the incidence of postoperative complications in the observation group was significantly lower. At 1, 4, and 12 weeks and the last follow-up, the VAS and WOMAC scores of the two groups gradually decreased, while the Lysholm score gradually increased. Moreover, the observation group improved significantly faster than the control group.

**Conclusions:** PRP injection showed faster pain reduction and functional recovery than conventional group.

### Keywords

Arthroscopy; Medial Meniscus; Meniscocapsular; Isolated occult medial meniscocapsular separation; Platelet-rich plasma.

## Introduction

Isolated occult medial meniscus capsule separation (IOMMCS) is a subtype of meniscus injury, comprising the separation of the outermost part of the meniscus from the joint capsule junction due to its rich blood supply and good healing ability [1-3]. Its clinical symptoms are not typical, and the pain is evident after intense activity or when the activity amount is significant, while the MRI results of the knee joint are often negative [4]. Outpatient doctors often give conservative treatment according to a simple knee joint sprain, prolonging the treatment time and affecting the clinical prognosis.

Usually, IOMMCS is seen in the medial meniscus in the clinic and can be accompanied by other ligament injuries, such as anterior cruciate ligament injury [5,6]. At present, there are few reports on IOMMCS treatment. Since IOMMCS is hidden under the complete knee synovial membrane, it is easy to miss diagnosis if the operation is not carefully observed or the damage is not understood [7].

The location and type of meniscus injury are essential to select the treatment and prognosis [8]. Since 2017, our hospital has combined platelet-rich plasma (PRP) to treat meniscus injuries. We also noticed that the incidence of IOMMCS has increased. Herein, we evaluated two suture methods: direct suture after routine freshness and latent suture after PRP injection filling. The diagnosis, treatment, and follow-up results of the two suture groups were summarized and reported.

## Materials and Methods

### Clinical data

The inclusion and exclusion criteria were:

1. Patients diagnosed with IOMMCS;
2. MRI examination of knee joint;
3. Arthroscopic examination and surgical treatment;
4. Patients with diabetes, severe immunosuppressive diseases, infectious diseases, stroke sequelae, malignant tumors, severe heart diseases, and liver and kidney dysfunction were excluded.

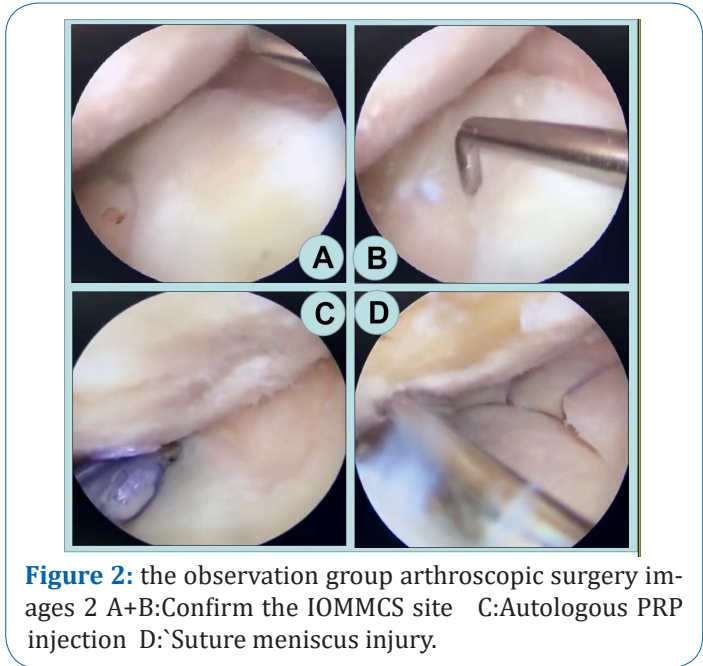
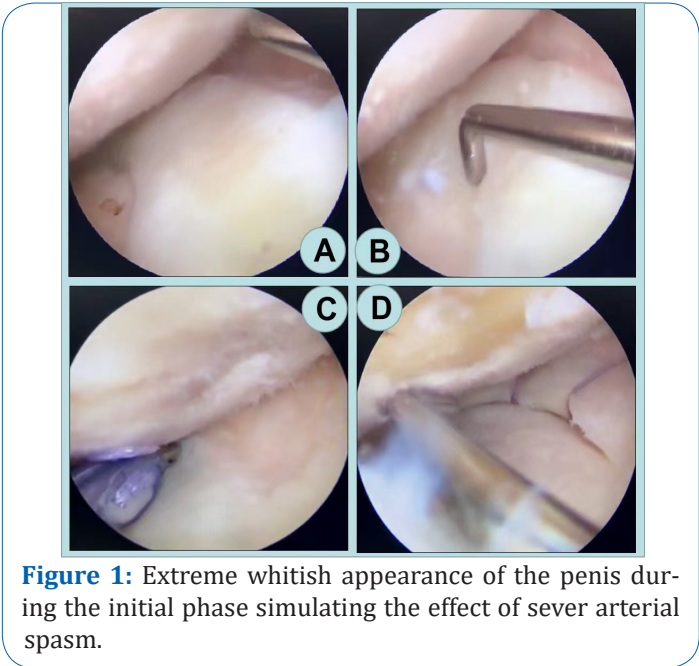
We conducted a retrospective analysis to summarize the clinical data of 67 patients admitted from 2007.1 to 2020.12 (Table 1), including 47 males and 20 females. Twenty-four cases were simple IOMMCS injuries, and 43 were combined intra-articular injuries. The average age was 41 years (range: 21-67 years), and the average time from injury to surgery was 10 months (range: 2-21 months). All patients had chronic medial knee pain. The MRI (1.5 T) examination showed no meniscus injury in IOMMCS, conservative treatment was ineffective, and IOMMCS was diagnosed by arthroscopy.

### Surgical suture and PRP preparation and application

Preparation of PRP: 20 mL of venous blood was centrifuged twice to produce 2 mL of platelet-rich plasma [9].

The two surgical suture methods were applied as follows:

The first was the conventional suture method. Under arthroscopy, the joint capsule junction of the meniscus was carefully explored through the anterior internal and lateral approaches with a probe hook. After the IOMMCS presence was clarified, the synovial wound was cleaned with a planer, and the synovial wound was freshened. Then, the All-Inside repair technology (FAST-FIX system) was used to suture according to the tear size, usually with 2-3 needles.



The second method was the PRP injection filling after the latent suture. Before PRP injection, the partial reduction was achieved by pushing the probe from the medial edge to the lateral edge of the meniscus. The IOMMCS was identified by arthroscopy with the first suture method but without the freshness treatment in the previous steps. Instead, the prepared PRP was injected into the IOMMCS synovial depression under arthroscopy until the synovial sac was filled and the depression disappeared. Finally, the All-Inside repair technique was used to suture 2-3 needles according to the tear size (Figures 1,2).

### Postoperative rehabilitation

Painless flexion and extension exercise of the knee joint was conducted within 1 week after the operation. After 3 weeks, the knee joint loading exercise gradually increased under hinge braces' protection. Four weeks later, depending on the recovery, the exercise gradually developed to full weight-bearing. After 3 months, the recovery was gradually normal.

## Follow-up and efficacy evaluation

The average postoperative follow-up was 31 months (range: 12 to 67 months). We evaluated the efficacy at different time points before and after surgery (preoperative, 1, 4, and 12 weeks, and the last follow-up) using resting-state VAS pain simulation, postoperative WOMAC scale (Likert version) subjective knee, and Lyscholm scale objective knee scores. We also recorded complications, such as local swelling duration, intra-articular hematoma, and lower extremity venous thrombosis.

**Table 1:** Comparison of general data between the two groups.

Groups	No. of patients (N)	Male/Female		Age (Y)	course of diseases (Month)	OP time (Min)	Combined damage or not	
		M	F				Yes	No
control	36	25	11	31 ± 4.7	13 ± 6.1	115 ± 16.7	13	23
PRP	31	22	9	29 ± 3.3	12 ± 8.3	121 ± 12.9	11	20
statistical quantity		0.0185		1.9483	0.5669	1.6254	0.0029	
P value		0.8918		0.0514	0.5727	0.1089	0.9571	

## Statistical Analysis

SPSS 19.0 software was used for statistical analyses. Measurement data are presented as means ± SD and analyzed by t-test or repeated measurement variance analysis. Enumeration data were analyzed by the  $\chi^2$  test. A  $p < 0.05$  was considered statistically significant.

## Results

### General data comparison

All patients were followed up. No significant differences were detected between the observation and control groups for gender distribution, age composition, disease duration, whether a compound injury occurred, and operation time (Table 1).

### Comparison of pain VAS and knee function scores in the resting state

Since the clinical manifestations of patients were mainly post-activity chronic pain and knee joint linear tenderness, local MR manifestations were often negative. Thus, we compared the VAS score, WOMAC subjective knee function, and Lysholm objective knee function scores between the observation and control groups in the resting state.

The two groups did not differ in the VAS score of pain in the resting state before the operation. After treatment, the VAS score of the control group gradually decreased from  $5.4 \pm 0.8$  before treatment to  $4.9 \pm 0.9$ ,  $3.3 \pm 0.3$ ,  $1.3 \pm 0.4$ , and  $1.1 \pm 0.3$  after 1, 4, and 12 weeks, and the last follow-up, respectively. Differences were statistically significant before and after 4 weeks. The VAS score of the observation group also

gradually reduced to  $3.6 \pm 0.3$ ,  $1.9 \pm 0.2$ ,  $1.2 \pm 0.1$ , and  $1.1 \pm 0.5$  after 1, 4, and 12 weeks, and the last follow-up, respectively, from  $5.3 \pm 0.9$  before treatment. Differences were statistically significant before and after the first week. The difference between the observation and the control groups was statistically significant in the fourth week. Therefore, the observation group had faster and better pain relief in the resting state compared to the control group.

**Table 2:** Comparison of VAS scores between the two groups before and after treatment in the resting state.

Groups	control	PRP	statistical quantity(t)	P value
preoperative	$5.4 \pm 0.8$	$5.3 \pm 0.9$	0.4815	0.6318
1 week after OP	$4.9 \pm 0.9$	$3.6 \pm 0.3$	7.6765	<0.01
4 week after OP	$3.3 \pm 0.3$	$1.9 \pm 0.2$	22.0869	<0.01
12 week after OP	$1.3 \pm 0.9$	$1.2 \pm 0.1$	0.6147	0.5409
final follow-up	$1.2 \pm 0.3$	$1.1 \pm 0.5$	1.0083	0.3137
Statistic (F)	86.3896	285.9265		
P value	<0.01	<0.01		

**Table 3:** Comparison of WOMAC scores between the two groups before and after surgical treatment.

Groups	control	PRP	statistical quantity(t)	P value
preoperative	$93.4 \pm 11.6$	$95.1 \pm 9.3$	0.6545	0.6849
1 week after OP	$81.9 \pm 5.1$	$75.2 \pm 6.8$	4.5993	<0.01
4 week after OP	$66.3 \pm 4.7$	$53.2 \pm 4.9$	11.1539	<0.01
12 week after OP	$56.7 \pm 5.2$	$49.3 \pm 3.2$	6.8771	<0.01
final follow-up	$49.1 \pm 67$	$45.7 \pm 3.7$	2.513	0.0145
Statistic (F)	267.2885	343.7143		
P value	<0.01	<0.01		

The WOMAC subjective knee joint function score did not differ between the observation and treatment groups before the operation. In the control group, the WOMAC scores were  $93.4 \pm 11.6$ ,  $81.9 \pm 5.1$ ,  $66.3 \pm 4.7$ ,  $56.7 \pm 5.2$ , and  $49.1 \pm 67$  before the operation and at weeks 1, 4, and 12 after the operation, respectively. The WOMAC scores were different before and at weeks 1, 4, and 12 weeks after the operation and the last follow-up, and the longer the time, the lower the score ( $p < 0.01$ , Table 3). At the same time, in the observation group, the WOMAC scores were  $95.1 \pm 9.3$ ,  $75.2 \pm 6.8$ ,  $53.2 \pm 4.9$ ,  $49.3 \pm 3.2$ , and  $45.7 \pm 3.7$  before operation and at weeks 1, 4, and 12 after the operation, respectively. There were significant differences in WOMAC scores between preoperative and postoperative follow-ups at each time point, and the score decreased with time ( $p < 0.01$ , Table 3). Moreover, the WOMAC scores significantly differed between the observation and control groups 1 week after the operation, and the difference was statistically significant until the last follow-up ( $p < 0.01$ , Table 3). These results demonstrated that arthroscopic surgical sutures significantly affect IOMMCS treatment. Meanwhile, arthroscopic PRP injection and filling-assisted latent suture have a faster and better effect on the recovery of subjective function of the knee joint.

The Lysholm objective knee joint function score did not differ between the observation and treatment groups before the operation. In the control group, Lysholm scores were  $72.3 \pm 7.1$ ,  $79.1 \pm 3.3$ ,  $84.1 \pm 4.7$ ,  $87.6 \pm 3.1$ , and  $91.7 \pm 4.5$  before operation and 1, 4, and 12 weeks after the operation, respectively. The Lysholm scores significantly differed before and 1, 4, and 12 weeks after the operation and the last follow-

**Table 4:** Comparison of Lysholm scores between the two groups before and after surgical treatment.

Groups	control	PRP	statistical quantity(t)	P value
preoperative	72.3 ± 7.1	71.6 ± 6.9	0.4076	0.6489
1 week after OP	79.1 ± 3.3	81.3 ± 4.2	2.3992	0.0193
4 week after OP	84.1 ± 4.7	89.5 ± 4.1	4.9713	<0.01
12 week after OP	87.6 ± 3.1	90.2 ± 4.8	2.6688	<0.01
final follow-up	91.7 ± 4.5	92.1 ± 3.1	0.4168	0.0678
Statistic (F)	101.2909	123.4907		
P value	<0.01	<0.01		

up, and the longer the time, the higher the score ( $p < 0.01$ , Table 3). Meanwhile, in the control group, the Lysholm scores were  $71.6 \pm 6.9$ ,  $81.3 \pm 4.2$ ,  $89.5 \pm 4.1$ ,  $90.2 \pm 4.8$ , and  $92.1 \pm 3.1$  at different time points before and 1, 4, and 12 weeks after the operation, respectively. The Lysholm scores significantly differed between the preoperative and postoperative follow-ups at different time points, and the score increased with time ( $p < 0.01$ , Table 3). Additionally, the Lysholm score differed between the observation and control groups 1 week after the operation. The difference was statistically significant until 12 weeks after the operation ( $p < 0.01$ , Table 3). Similar to the WOMAC subjective function score before and after surgery, these results showed that arthroscopic surgical suture has a significant effect on IOMMCS treatment, and arthroscopic PRP injection filling-assisted latent suture has a faster recovery effect on the objective function of the knee joint.

### Postoperative complications in two groups

The postoperative swelling duration between the control and observation groups was significantly different ( $6.1 \pm 3.3$  and  $3.3 \pm 1.2$  W, respectively;  $t = 4.7291$ ,  $p < 0.01$ ). The incidence of other complications in the control group was 8.3% (3/36). Among them, two cases of knee joint hemorrhage were cured by elastic bandage after joint puncture and blood extraction, and one case of symptomatic deep venous thrombosis of lower extremities was cured by conservative symptomatic treatment. We did not detect complications in the observation group. None of the cases underwent reoperation.

### Discussion

IOMMCS is a new subtype of meniscus injury, rarely reported in the literature [1]. Different from the evident fissure characteristics at the plate-cyst interface of the isolated MCS, IOMMCS does not have a prominent fissure, showing the concave gap at the plate-cyst interface, the relaxation of the meniscus and synovial membrane, and the microscopic characteristics of the probe tip that can reach the tibial plateau through the synovial membrane below the damage site [5,6]. The clinical features of IOMMCS were mainly chronic medial knee pain and local tenderness around the joint line related to activity [10,11]. Isolated MCS is common in women, and medial MCS is often associated with an anterior cruciate ligament injury and medial MCS tear [12]. Herein, IOMMCS, like isolated MCS, could be combined with a cruciate ligament injury and other types of meniscus injury. IOMMCS has a certain correlation with isolated MCS. There are also reports of medial occult MCS without other intra- and extra-articular injuries in patients with 20-30

years, non-contact knee injury, no history of violent trauma, and MR examination often without meniscus injury. Consistent with this study, the cases were also chronic non-violent injuries [13,14]. The MR examination showed a negative local meniscus, but I-II meniscus injuries were occasionally reported. This group of patients had 21-67 years, comprising more men than women, and could also be combined with other intra-articular injuries. Thus, the differences might be related to varied standards and sample sizes [15]. Here, some IOMMCS cases also showed simple occult MCS without other intra-articular injuries, which might be related to meniscus morphology, chronic overload of knee capsule, imbalance of soft tissue tension, degeneration, and other factors, and also part of the pathological manifestations of knee arthritis [16]. It might also be closely connected with the medial meniscus and the articular capsule, medial collateral ligament, posterior oblique ligament, and semimembranous muscle, resulting in fixation of the meniscus by femoral tibial clamp during sudden knee torsion, and the medial occult separation caused by the force traction of the semimembranous muscle-posterior oblique ligament-articular capsule [17]. Another part of our current IOMMCS cases presented other joint injuries, which might be the combined result of knee joint injuries at different stages and parts [18,19].

There is no consensus on the effect of different suture methods and techniques on the recovery of cystic separation injury. Herein, we compared two suture methods. The observation group received PRP injection filling using latent sutures, while the control group received the traditional method in the knee. In the observation group, the VAS, IKDC, and Lysholm scores improved faster [20,21]. The meniscus joint capsule area has an abundant blood supply and strong healing ability and can be sutured and repaired. Liu et al. reported that only fresh wound treatment could achieve a good curative effect for stable meniscus synovial tears [22]. However, many studies have shown that medial meniscus instability and wear with medial femoral condyle cartilage reduce the possibility of spontaneous healing and lead to meniscus and cartilage damage progression [23-26]. Therefore, if the All- or Out-inside suture repair is adopted, the anatomical repair of IOMMC injury is an important guarantee for restoring meniscus stability, promoting healing, and improving the IKDC and Lysholm scores of patients' knee joints [27].

PRP is an autologous blood extract. Many in vitro and animal studies have shown that platelet-derived and other growth factors contained in PRP can increase the activity of meniscus cells and stimulate their repair [12,28]. Currently, PRP has been widely used in treating diseases based on tendons, muscles, ligaments, and cartilage [29]. Moreover, our previous studies have shown that PRP treatment can promote the healing of knee joint chronic meniscus injury, relieve pain, improve signs, and improve the quality of life, with good therapeutic effects [30].

Recently, scholars have reviewed the literature and shown evidence for PRP in meniscus repair in the clinic. Arthroscopic meniscus repair combined with PRP treatment can reduce joint pain, improve knee joint function in the short term, and significantly reduce the reoperation rate of meniscus repair [31]. Here, the results of the observation group showed that, compared to the control group, the VAS score significantly decreased in postoperative pain, especially in the early stage, consistent with previous studies [32]. Besides, regarding postoperative complications, the swelling recovery is faster, and the joint cavity hemorrhage and lower extremity venous thrombosis are better controlled [33]. This might be because when PRP

is used for enhanced meniscus repair, it can regulate the meniscus environment by introducing autologous blood products into the target tissue, leading to inflammation alleviation and promoting cartilage formation [34].

However, this was a single-center retrospective study with a small sample size and cannot provide more detailed epidemiological and pathophysiological features [35]. In the future, multi-center studies with large samples will be needed.

In summary, IOMMCS is a unique meniscus-joint capsule injury, and arthroscopic suture repair technology is reliable with the intraoperative injection of PRP filling auxiliary for potential suture repair. Compared to the traditional suture method, it can quickly relieve pain, improve knee function score, and reduce postoperative complications, being worthy of promotion and further research and application.

## Conclusions

Endoscopic suture repair is an effective method for treating symptomatic IOMMCS. The submerged suture after PRP injection has a faster onset and fewer complications than the conventional fresh suture, being worthy of popularization and application.

## Declarations

**Informed consent statement:** Informed consent was obtained from all subjects involved in the study.

**Conflicts of interest:** The authors declare no conflict of interest.

## References

1. Dugas JR, Barrett AM, Beason DP, Plymale MF, Fleisig GS, et al. Tibiofemoral contact biomechanics following meniscocapsular separation and repair. *International journal of sports medicine*. 2015; 36.
2. Hirtler L, Unger J, Weninger P. Acute and chronic menisco-capsular separation in the young athlete: diagnosis, treatment and results in thirty seven consecutive patients. *International Orthopaedics*. 2015.
3. Lynn BW, Adetola BA. Angiogenic approaches to meniscal healing. *Injury*. 2018; 49.
4. Kim YJ, Sung-Bin L, Chin-Hyung C, Ki-Seok H, et al. The Regenerative effects of Platelet-Rich Plasma and Enamel Matrix Protein on Grade III Furcation defects in beagle dogs. *The Journal of the Korean Academy of Periodontology*. 2014; 35: 823-823.
5. Lecouvet F, Van Haver T, Acid S, Perlepe V, Kirchgesner T, et al. Magnetic resonance imaging (MRI) of the knee: Identification of difficult-to-diagnose meniscal lesions. *Diagnostic & Interventional Imaging*. 2018; 99: 55.
6. Chahla J, Dean CS, Moatshe G, Mitchell JJ, Cram TR, et al. Meniscal Ramp Lesions: Anatomy, Incidence, Diagnosis, and Treatment. *The Orthopaedic Journal of Sports Medicine*. 2016; 4.
7. Wei D, Chen XA, Gu XD, Li PC, Wei XC, et al. Arthroscopic surgery combined with platelet-rich plasma for meniscus injury: a Meta analysis. *Zhongguo gu shang = China journal of orthopaedics and traumatology*. 2021; 34.
8. Kumar NS, Edgar C, Spencer T, Ware JK, Reed DN, et al. Anatomic Repair of Posteromedial Meniscocapsular Separation Using an All-Inside Technique. *Arthroscopy Techniques*. 2017.
9. Dejneke M, Moreira H, Płaczkowska S, Barg E, Reichert P, et al. Effectiveness of Lateral Elbow Tendinopathy Treatment Depends on the Content of Biologically Active Compounds in Autologous Platelet-Rich Plasma. *J Clin Med*. 2022; 11.



10. Rubinstein RA, DeHaan A, Baldwin JL. Posterior medial meniscus detachment: a unique type of medial meniscal tear. *The journal of knee surgery*. 2009; 22.
11. Bollen SR. Posteromedial meniscocapsular injury associated with rupture of the anterior cruciate ligament: a previously unrecognized association. *Journal of Bone & Joint Surgery*. 2010; 92: 222-223.
12. Sánchez M, Jorquera C, López de Dicastillo L, Fiz N, Knörr J, et al. Real-world evidence to assess the effectiveness of platelet-rich plasma in the treatment of knee degenerative pathology: a prospective observational study. *Therapeutic advances in musculoskeletal disease*. 2022; 14: 1759720X221100304.
13. Joshi A, Usman S, Sabnis B, Kini A, et al. Repairing Posteromedial Meniscocapsular Separation: A Technique Using Inside-Out Meniscal Repair Needles. *Arthroscopy Techniques*. 2016; 5: e23-e25.
14. Hutchinson ID, Moran CJ, Potter HG, Warren RF, Rodeo SA. Restoration of the meniscus: form and function. *American Journal of Sports Medicine*. 2013; 42: 987-98.
15. Keller RE, O'Donnell EA, Medina GIS, Linderman SE, Cheng TTW, et al. Biological augmentation of meniscal repair: a systematic review. *Knee Surgery, Sports Traumatology, Arthroscopy*. 2022; 30.
16. Herdea A, Struta A, Derihaci RP, Ulici A, Costache A, et al. Efficiency of platelet-rich plasma therapy for healing sports injuries in young athletes. *Experimental and therapeutic medicine*. 2022; 23.
17. Migliorini F, Cuozzo F, Cipollaro L, Oliva F, Hildebrand F, et al. Platelet-rich plasma (PRP) augmentation does not result in more favourable outcomes in arthroscopic meniscal repair: a meta-analysis. *Journal of Orthopaedics and Traumatology*. 2022; 23.
18. Xiao W, Yang YT, Xie WQ, He M, Liu D, et al. Effects of Platelet-Rich Plasma and Bone Marrow Mesenchymal Stem Cells on Meniscal Repair in the White-White Zone of the Meniscus. *Orthopaedic surgery*, 2021.
19. McClain WD, DeFoor MT, Patzkowski JC. Meniscus Repair Techniques. *Sports Medicine and Arthroscopy Review*. 2021; 29.
20. Yang C, Hung KT, Weng CJ, Chao-Yu Chen A, Hsu KY, et al. Clinical Outcomes of Meniscus Repair with or without Multiple Intra-Articular Injections of Platelet Rich Plasma after Surgery. *Journal of Clinical Medicine*. 2021; 10.
21. Lăzărescu AE, Văduva AO, Hogeia GB, Croicu C, Pătrașcu Jra JM, et al. Comparing PRP and bone marrow aspirate effects on cartilage defects associated with partial meniscectomy: a confocal microscopy study on animal model. *Romanian journal of morphology and embryology = Revue roumaine de morphologie et embryologie*, 2021 ; 62.
22. Knapik DM, Evuarherhe Jr A, Frank RM, Steinwachs M, Rodeo S, et al. Nonoperative and Operative Soft-Tissue and Cartilage Regeneration and Orthopaedic Biologics of the Knee: An Orthoregeneration Network (ON) Foundation Review. *Arthroscopy: The Journal of Arthroscopic and Related Surgery*, 2021; 37.
23. Bailey L, Weldon M, Kleihege J, Lauck K, Syed M, et al. Platelet-Rich Plasma Augmentation of Meniscal Repair in the Setting of Anterior Cruciate Ligament Reconstruction. *The American journal of sports medicine*. 2021; 49.
24. Eun KS. Biomechanical Study on Meniscus Repair Techniques. *Journal of the Korean orthopaedic association*. 1991; 26.
25. Filardo G, Kon E, Roffi A, Di Matteo B, Merli ML, et al. Platelet-rich plasma: why intra-articular? A systematic review of pre-clinical studies and clinical evidence on PRP for joint degeneration. *Knee Surgery Sports Traumatology Arthroscopy*. 2015; 23: 2459-2474.
26. Kazunari Ishida RKMM. The regenerative effects of platelet-rich plasma on meniscal cells in vitro and its in vivo application with biodegradable gelatin hydrogel. *Tissue Engineering Part A*. 2007; 13: 1103-1112.
27. Hagmeijer MH, Korpershoek JV, Crispim JF, Chen LT, Jonkheijm P, et al. The regenerative effect of different growth factors and platelet lysate on meniscus cells and mesenchymal stromal cells and proof of concept with a functionalized meniscus implant. *Journal of tissue engineering and regenerative medicine*. 2021; 15: 648-659.
28. Seil R, Becker R. Time for a paradigm change in meniscal repair: save the meniscus!. *Knee Surgery Sports Traumatology Arthroscopy*. 2016; 24: 1-3.

29. Nobutake O, Seil R, Krych AJ, Koga H. Surgical treatment of complex meniscus tear and disease: state of the art. *Journal of ISAKOS: Joint Disorders & Orthopaedic Sports Medicine*. 2020; 6.
30. Wen-Li D, Zhang H, Lin ZM, Shi ZJ, Wang J, et al. Efficacy of platelet-rich plasma in arthroscopic repair for discoid lateral meniscus tears. *BMC musculoskeletal disorders*. 2019; 20.
31. Houck DA, Kraeutler MJ, Thornton LB, McCarty EC, Bravman JT Treatment of Lateral Epicondylitis with Autologous Blood, Platelet-Rich Plasma, or Corticosteroid Injections: A Systematic Review of Overlapping Meta-analyses. *The Orthopaedic Journal of Sports Medicine*. 2019; 7.
32. Bennell KL, Hunter DJ, Paterson KL. Platelet-Rich Plasma for the Management of Hip and Knee Osteoarthritis. *Current Rheumatology Reports*. 2017; 19: 24.
33. Hu Z. Therapeutic effects of platelet-rich plasma injection in treatment of chronic meniscus injury. *Chinese Journal of Joint Surgery(Electronic Edition)*, 2019.
34. Bertrand S, Conteduca J, Thaumat M, Gunepin FX, Seil R, et al. Hidden Lesions of the Posterior Horn of the Medial Meniscus. *The American Journal of Sports Medicine*. 2014; 42.
35. Huang Y, Bornstein MM, Lambrichts I, Yu HY, Constantinus P, et al. Platelet-rich plasma for regeneration of neural feedback pathways around dental implants: a concise review and outlook on future possibilities. *Int J Oral Sci*. 2017; 9: 1-9.

**Manuscript Information:** Received: December 12, 2022; Accepted: January 10, 2023; Published: January 20, 2023

**Authors Information:** Wenhui Li; Zhengbo Hu\*; Penghuan Wu; Zhinian Zhong; Xiao Wei\*

<sup>1</sup>Department of Orthopaedics, Shaoguan First People's Hospital, Shao Guan Hospital Southern Medical University, Guangdong, 512000, China.

**Citation:** Li W, Hu Z, Wu P, Zhong Z, Wei X. Effects of two suture methods under arthroscopy on isolated occult medial meniscocapsular separation. *Open J Clin Med Case Rep*. 2023; 1965.

**Copy right statement:** Content published in the journal follows Creative Commons Attribution License (<http://creativecommons.org/licenses/by/4.0>). © **Zhengbo Hu & Xiao Wei (2023)**

**About the Journal:** Open Journal of Clinical and Medical Case Reports is an international, open access, peer reviewed Journal focusing exclusively on case reports covering all areas of clinical & medical sciences.

Visit the journal website at [www.jclinmedcasereports.com](http://www.jclinmedcasereports.com)

For reprints and other information, contact [info@jclinmedcasereports.com](mailto:info@jclinmedcasereports.com)