

## A rare clinical picture of oral lichen planus in the hard palate

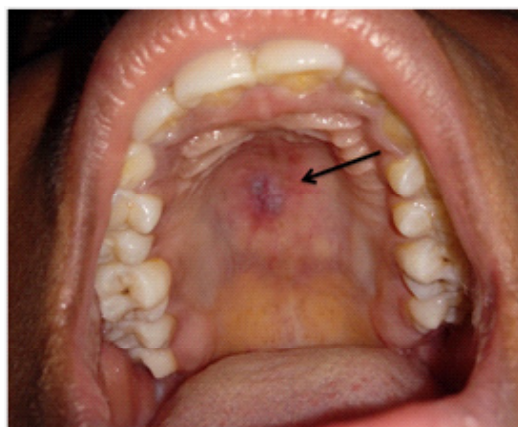
\*Corresponding Author: Sreelakshmi N Nair, MDS

Oral Medicine and Radiology, Santhosh Dental Clinic, Kanhangad, Kasargod Dist, Kerala, India.

Email: sreelakshmiathul13@gmail.com

### Clinical Image Description

A 20-year-old physically fit female patient came to the Department of Oral Medicine and Radiology, with a complaint of burning sensation in relation to the hard palate for 5 days, which aggravated with eating spicy food and on touching the palate and got relieved when at rest. On oral examination, a solitary, well-demarcated, erythematous area surrounded by a grayish white lesion with interlacing pattern was seen on the hard palate. It was ovoid in shape measuring about 1 cm in diameter. The lesion was seen close to the right side of the midline and almost crossing it. On palpation, there was tenderness. The lesion was non scrapable and did not bleed. A fresh tissue specimen taken from the lesion by punch biopsy was sent for direct immunofluorescence test and the results showed deposits of fibrinogen in a shaggy pattern along the Basement Membrane Zone (BMZ) and cytooid bodies IgM and IgA. Based on the clinical features and the immunofluorescence test results, the lesion was diagnosed as erosive lichen planus of the hard palate.



Grayish white lesion with erythematous area on the palate

**Manuscript Information:** Received: September 12, 2020; Accepted: October 05, 2020; Published: October 30, 2020

**Authors Information:** Sreelakshmi N Nair, MDS\*

Oral Medicine and Radiology, Santhosh Dental Clinic, Kanhangad, Kasargod Dist, Kerala, India.

**Citation:** Sreelakshmi NN. A rare clinical picture of oral lichen planus in the hard palate. Open J Clin Med Case Rep. 2020; 1696.

**Copy right statement:** Content published in the journal follows Creative Commons Attribution License (<http://creativecommons.org/licenses/by/4.0>). © **Sreelakshmi NN 2020**

**About the Journal:** Open Journal of Clinical and Medical Case Reports is an international, open access, peer reviewed Journal focusing exclusively on case reports covering all areas of clinical & medical sciences.

Visit the journal website at [www.jclinmedcasereports.com](http://www.jclinmedcasereports.com)

For reprints and other information, contact [info@jclinmedcasereports.com](mailto:info@jclinmedcasereports.com)