

Hemoperitoneum caused by accessory spleen rupture – An unexpected finding

Cristina Monteiro*; Bruno Ribeiro da Silva; Alberto Midões

*Corresponding Author: Cristina Monteiro

General Surgery, Unidade Local de Saúde do Alto Minho, Hospital de Santa Luzia, Estrada de Santa Luzia, Rua Arquitecto André Soares, 92 - Bloco 1A H11 4935-165 Viana do Castelo, Portugal.

Phone: 00351-914-202-312; Email: cristina_f_monteiro@hotmail.com

Clinical Image Description

Accessory spleens are a consequence of fetal differentiation failures. Ectopic spleens develop in atypical locations in a 10-30% of cases [1,2].

68-year-old male patient who had an incisional and umbilical hernia laparoscopic repair with mesh is discharged one day after surgery. Later that day, returns to the Hospital presenting an acute abdomen. A laparotomy was performed disclosing hemoperitoneum caused by an omentum highly vascularized mass (Figures 1 & 2).

The specimen was analyzed by the Pathology Department revealing a ruptured accessory spleen.

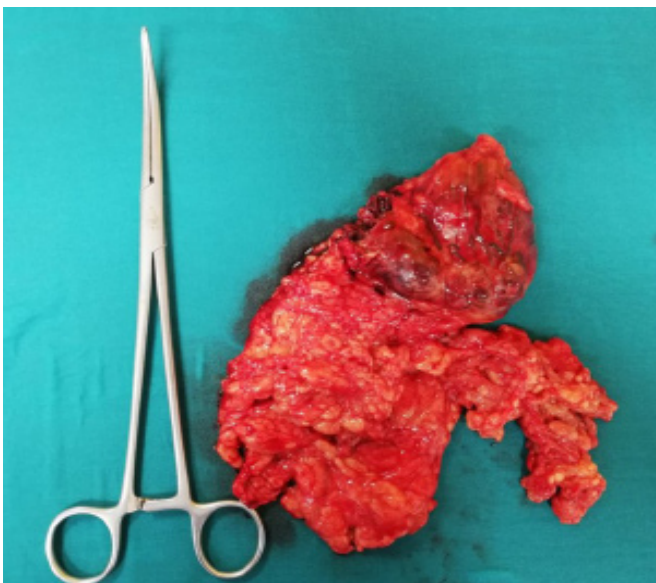


Figure 1

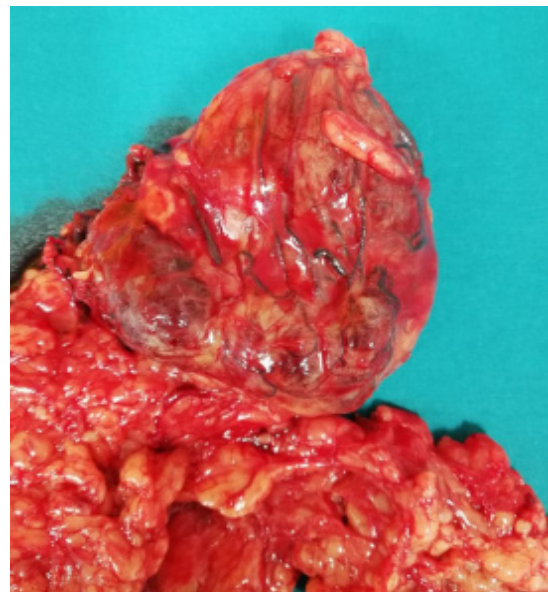


Figure 2

References

1. Landmann A, et al. Accessory spleen presenting as acute abdomen: A case report and operative management, Journal of Pediatric Surgery Case Reports. 2016; 12: 9-10.
2. Landmann et al, Accessory spleen presenting as acute abdomen: A case report and operative management. Journal of Pediatric Surgery Case Reports. 2016; 12.

Manuscript Information: Received: June 28, 2020; Accepted: August 06, 2020; Published: August 31, 2020

Authors Information: Cristina Monteiro*; Bruno Ribeiro da Silva; Alberto Midões
General Surgery - Unidade Local de Saúde do Alto Minho – Hospital de Santa Luzia, Estrada de Santa Luzia, Viana do Castelo, Portugal

Citation: Monteiro C, Ribeiro da Silva B, Midões A. Hemoperitoneum caused by accessory spleen rupture – An unexpected finding. Open J Clin Med Case Rep. 2020; 1685.

Copy right statement: Content published in the journal follows Creative Commons Attribution License (<http://creativecommons.org/licenses/by/4.0>). © **Monteiro C 2020**

About the Journal: Open Journal of Clinical and Medical Case Reports is an international, open access, peer reviewed Journal focusing exclusively on case reports covering all areas of clinical & medical sciences.

Visit the journal website at www.jclinmedcasereports.com

For reprints and other information, contact info@jclinmedcasereports.com