

Femoral aneurysm

Mariana Leite*; Antonio Assuncao

***Corresponding Author(s): Mariana Leite**

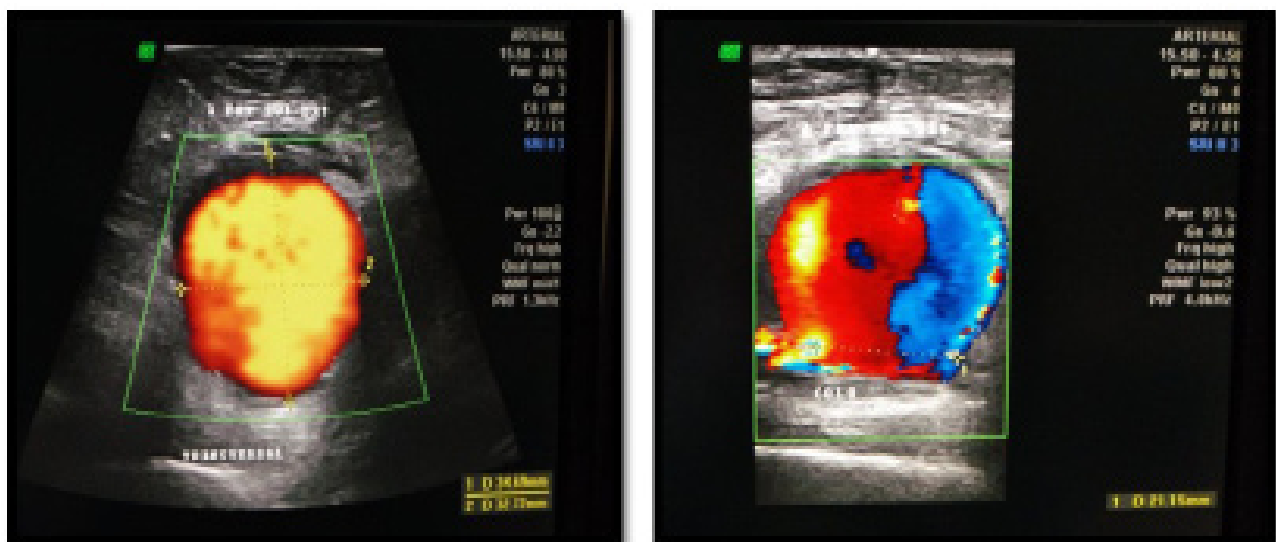
General Surgery of Local Health Unit of Alto Minho – Santa Luzia Hospital, Rua Arquitecto André Soares, 92 – Bloco 1A H11, 4935-165 Viana do Castelo, Portugal

Phone: 0035-1969-526-676; Email: marianalsleite@gmail.com

Description

A clinical case of a men, 65-year-old, with medical history of ischemic heart disease, hypertension, dyslipidemia and ulcerative colitis, who went a vascular surgeon consultation because of sudden onset of pulsatile and painful swelling in the medial face of the right thigh. The patient denied a trauma history before the swelling appear. Diagnostic tests, namely arterial doppler (Figures 1 & 2), showed the presence of an aneurysm in the proximal third of the superficial femoral artery (50mm x 35mm x 33mm) in the right thigh, with no signs of thrombosis.

The patient was submitted to a partial aneurysmectomy (Figure 4) and limb revascularization with a femorofemoral interposition bypass with inverted large saphenous vein (Figure 5). The histopathological exam revealed a true aneurysm.



Figures 1 & 2: Arterial Doppler revealing an aneurysm of the superficial femoral artery

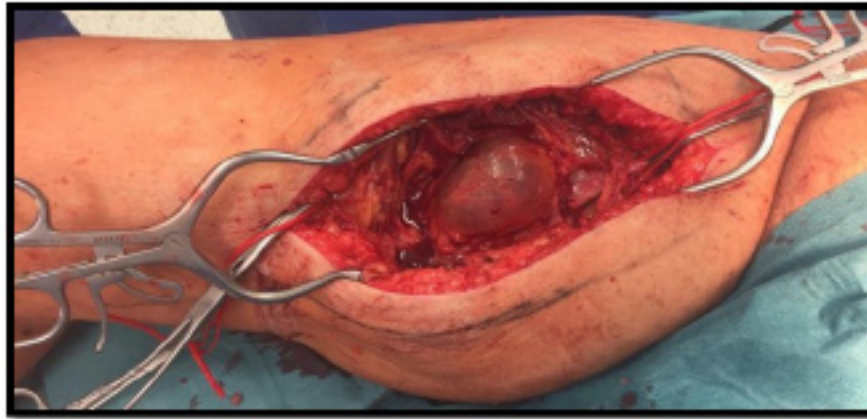
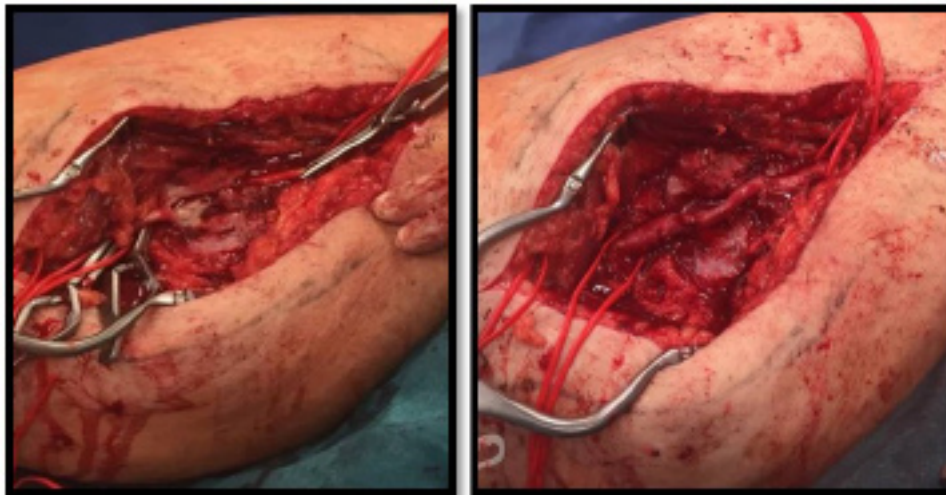


Figure 3: Superficial femoral artery aneurysm of the right leg



Figures 4 & 5: Partial aneurysmectomy of the superficial femoral artery and femorofemoral interposition bypass with inverted saphenous vein leg

Manuscript Information: Received: October 02, 2019; Accepted: March 16, 2020; Published: March 31, 2020

Authors Information: Mariana Leite^{1*}; Antonio Assuncao²

¹General Surgery of Local Health Unit of Alto Minho – Santa Luzia Hospital, Rua Arquitecto André Soares, 92 – Bloco 1A H11, 4935-165 Viana do Castelo, Portugal

²Vascular Surgery of Braga Hospital – Sete Fontes, São Victor 4710-243 Braga, Portugal

Citation: Leite M, Assuncao A. Femoral aneurysm. Open J Clin Med Case Rep. 2020; 1642.

Copy right statement: Content published in the journal follows Creative Commons Attribution License (<http://creativecommons.org/licenses/by/4.0>). © Leite M 2020

About the Journal: Open Journal of Clinical and Medical Case Reports is an international, open access, peer reviewed Journal focusing exclusively on case reports covering all areas of clinical & medical sciences.

Visit the journal website at www.jclinmedcasereports.com

For reprints and other information, contact info@jclinmedcasereports.com