

Defying death in Breast Cancer

Arvind Navaneethkumar; Wan Zainira Wan Zain*; Maya Mazuwin Yahya

***Corresponding Author(s): Wan Zainira Wan Zain**

Department of Surgery, School of Medical Sciences, Universiti Sains Malaysia Health Campus, Kota Bharu, Kelantan, Malaysia

Email: zainira@usm.my

Abstract

A 78 -year -old lady with left breast cancer initially diagnosed 18 years ago but defaulted treatment, represented again 8 years later with advanced left breast cancer with TNM staging of T4bN3M1 with suspected lung metastasis. She initially completed neoadjuvant chemotherapy with 6 cycles of Taxotere, Adriamycin and Cyclophosphamide (TAC) regime and followed by Toilet Mastectomy, Axillary Clearance and immediate chest wall reconstruction with Transverse Rectus Abdominis Myocutaneous Flap (TRAM) flap (figure 2,3,4). She had an uneventful post operation, recovered well and was put on hormonal therapy. The patient had progression of disease when she was found to have a right adnexal mass and increasing lung metastasis in her surveillance program in 2016. However, she refused surgical nor chemotherapy. Patient has been followed up well for the past 9 years, has no active issues and has good quality of life despite her disease. In conclusion, we would like to highlight her remarkable overall survival status despite defaulting and refusing our treatment on numerous occasions.

Keywords

metastatic breast cancer; infiltrating ductal carcinoma; overall survival; oligometastasis

Introduction

Breast cancer remains the most common cancer diagnosed amongst women in Malaysia and is the second highest cause of cancer overall. Breast cancer represents a heterogenous array of vast disease subtypes which has unique molecular subtypes and distinct clinical features. Despite the advances in health care and in the management of breast cancer, approximately one third of patients will finally develop metastatic breast cancer [1]. The prognosis of metastatic breast cancer is very discouraging. According to the national cancer database in 2013, the 5 year survival rate is 15%, and only 5% of those are anticipated to be disease free and alive at 5 years with a grim median survival rate of 8-24 months [2]. Despite that, here we report the case of a patient with metastatic breast cancer who achieved long term survival of 10 years despite being non-compliant to treatment options. Her case is followed by a discussion on reasons on why

she has had this miraculous survival.

Case Presentation

A Madam S, is a 78 -year- old lady initially presented to the breast clinic 18 years ago with a vague left breast mass and was planned for workup but subsequently defaulted. She represented again 8 years later unfortunately progressing to advanced left breast cancer with suspected lung metastasis (Figure 1). She was staged , and her tissue biopsy revealed to be infiltrating ductal carcinoma, with Bloom Richardson grade of 2, with hormonal status of Estrogen Receptor (ER)/Progesterone Receptor (PR)/Human Epidermal Receptor 2 of positive/positive/negative. Computed tomography of Thorax, Abdomen and pelvis (CT-TAP) revealed large ulcerating enhancing left breast tissue with maximum thickness of ulcer measuring 3.0 cm. The lesion extends superiorly to clavicular level, laterally to axillary region and there was no clear plane with the left pectoralis major and latissimus dorsi, which is suggestive of involvement. Small right lung nodules noted, possibly lung metastasis. TNM staging was T4BN2M1. She completed neoadjuvant chemotherapy 6 cycles of Taxotere, Adriamycin and Cyclophosphamide (TAC) regime. She then underwent a Toilet Mastectomy, Axillary Clearance and immediate chest wall reconstruction with Transverse Rectus Abdominis Myocutaneous Flap (TRAM) flap (Figure 2). Histopathology examination (HPE) returned as infiltrating ductal carcinoma, not otherwised specified (NOS) of the breast (Bloom Richardson Grade 11). The hormone status was also a favourable ER positive/PR positive/HER2 positive and free margins. Subsequently she was well post-surgery and was started on letrozole which was continued till date (Figure 3). She was on close surveillance with regular CT scans of Thorax, abdomen and pelvis and mammograms and her disease was stable. Several years later, it was noted her lung lesions to be becoming larger although clinically she had no apparent symptoms and on CT scan she also had a cystic right adnexal mass most likely arising from the right ovary, suspecting to be a Krukenberg Tumour. She was referred to the gynecologist for which she was advised for Total Abdominal Hysterectomy and Bilateral Salphoorectomy but she refused. She also refused further chemotherapy for her disease progression. She was restarted on hormonal therapy indefinitely till disease progression. Till date despite she refusing further surgery/chemotherapy for her disease progression, she has defied death hence,her remarkable scenario is impetus for our case report (Figure 4).

Discussion

Metastatic breast cancer (MBC) as stated before has a rather grim prognosis. Usually the goal of treatment is the control of the disease and disease related complications, but treatments can occasionally lead to progression free or disease- free state leading to long term survival amongst MBC patients.

The prognosis relies on multiple complex factors which may play a part in influencing one's overall survival. For starters, is the hormonal status of the primary tumour. It is often thought that patient's with a positive hormonal status i.e positive estrogen receptor (ER), progesterone receptor factor (PR) and human epidermal growth factor 2 (HER2) receptor will lead to a better prognosis. In a recent study in Japan, it was concluded that the proportion of patients with longer disease free survival and the proportion of patients whom were hormone sensitive were noticeably higher in long term survivors [3]. In our subject, she was

fortunately hormone status positive which could have helped in her to survive her ordeal to this day.

Along with hormonal status, the HER2 status also plays a part in extending survival. The median survival of patients with (HER2)-positive metastatic breast cancer (MBC) has more than doubled, since the discovery of HER2-targeted treatments: it has increased from less than 2 years in 2001 (prior introduction of trastuzumab) to more than 4 years in 2017 [4]. However, since the cost of HER2- targeted treatment is costly, it is still a rarity to use it in our country. Our patient was not offered targeted therapy, but was put on long term hormonal therapy. A retrospective study has shown that hormonal therapy, whether in the form of an aromatase inhibitor or tamoxifen, provides a survival benefit when added to chemotherapy in patients with HR-positive/HER2-positive primary breast cancer [5].

Another factor postulated is oligometastasis. This is defined as having a solitary or few detectable metastasis. According to an another Japanese study, they identified 75 cases with oligometastasis breast cancer in their 30-year experience, and showed a 10-year overall survival rate (OSR) of 59.2% and a 10-year relapse-free rate (RFR) of 27.4%. They also showed that the cases with only single organ involvement were associated with a better survival with figures for 10-year OSR of 73% and a 10-year RFR of 42%, hence having stable disease progression [6]. This can be related in our case report as our survivor had only one documented metastasis, which was in the lungs.

A population- based study in Geneva reported that the total surgical removal of breast tumour with free margins is a positive prognostic factor in improving the chances of extending overall survival. They reported that women whom underwent surgery to remove the tumor had a 50% reduction in mortality compared to those whom did not go under the knife [7]. Likewise, in our case report, we managed to remove the patient's primary tumour with clear margins despite the fact she defaulted numerous times.

Despite MBC remaining fundamentally incurable, anthracycline and taxane- based chemotherapy have traditionally been used in patients with MBC. However, despite having a large share of randomized clinical trials showing improvements in response rates, few have revealed clear survival benefits. Nevertheless, recently a few trials have concluded that taxane- based chemotherapy have showed a survival, albeit modesty with increased survival rates up to 3 months [8]. Our patient was also given a taxane- based chemotherapy, taxore (DACOTEXEL) together with anthracycline which may have also help boost her survival rates.

Conclusion

MBC is undoubtedly incurable, but if we can institute early surgical treatment and manage to complete chemotherapy and with favourable factors like positive hormonal status, one can expect a longer overall survival than expected.

Figures

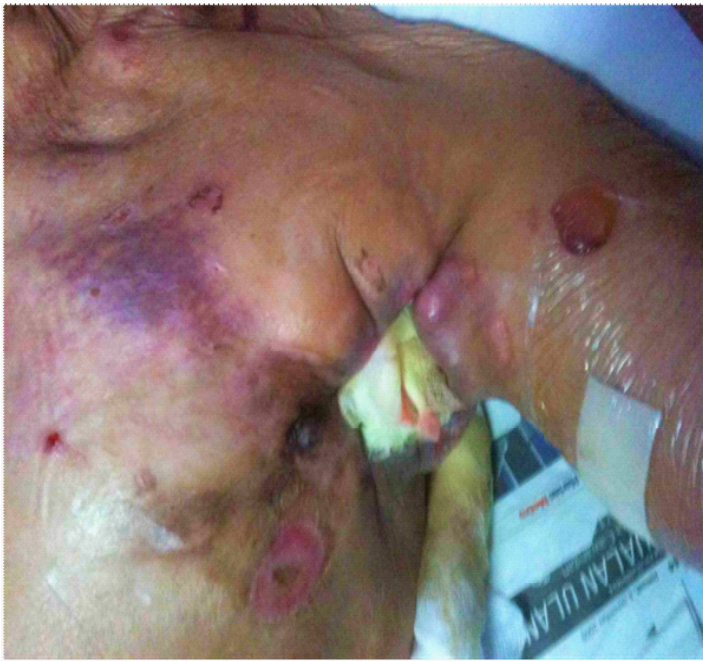

Figure 1: When represented with metastastic breast cancer after defaulting

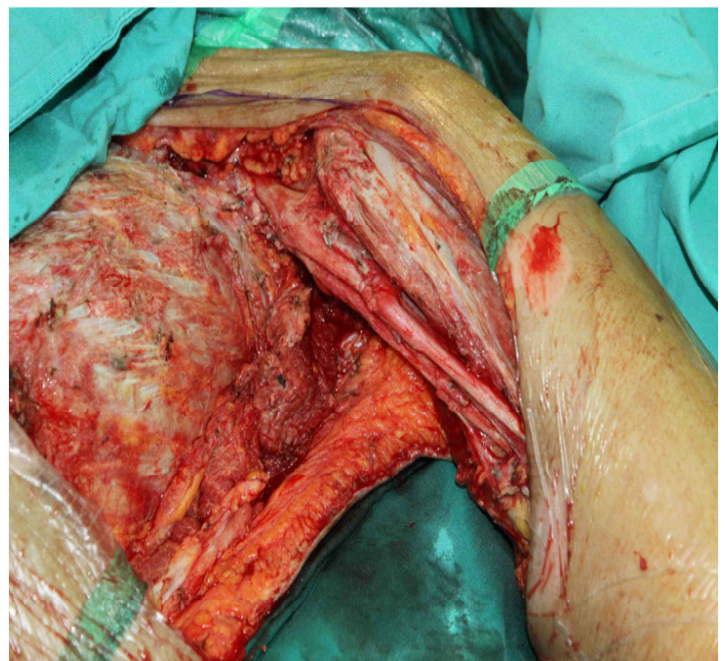


Figure 2: Intraoperative picture

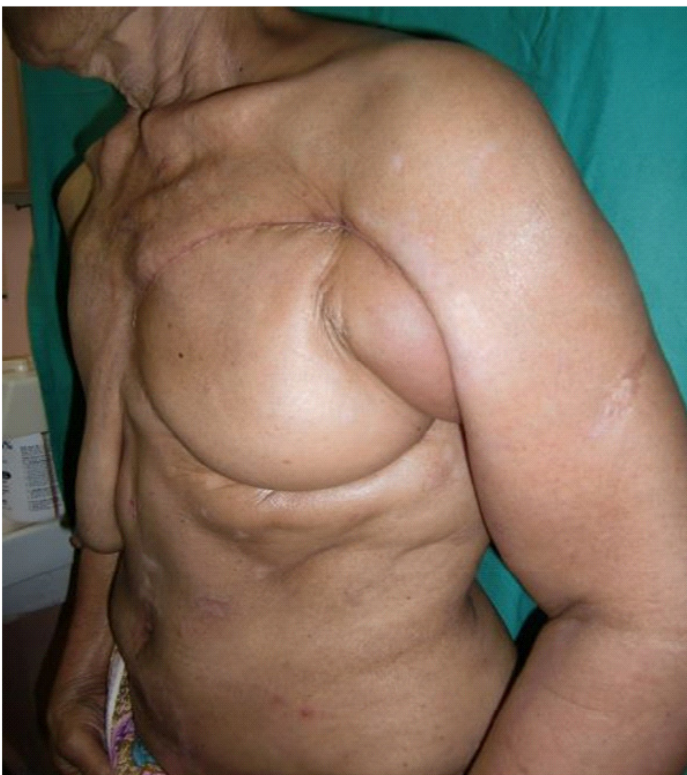

Figure 3: 4 months post procedure of mastectomy and tram

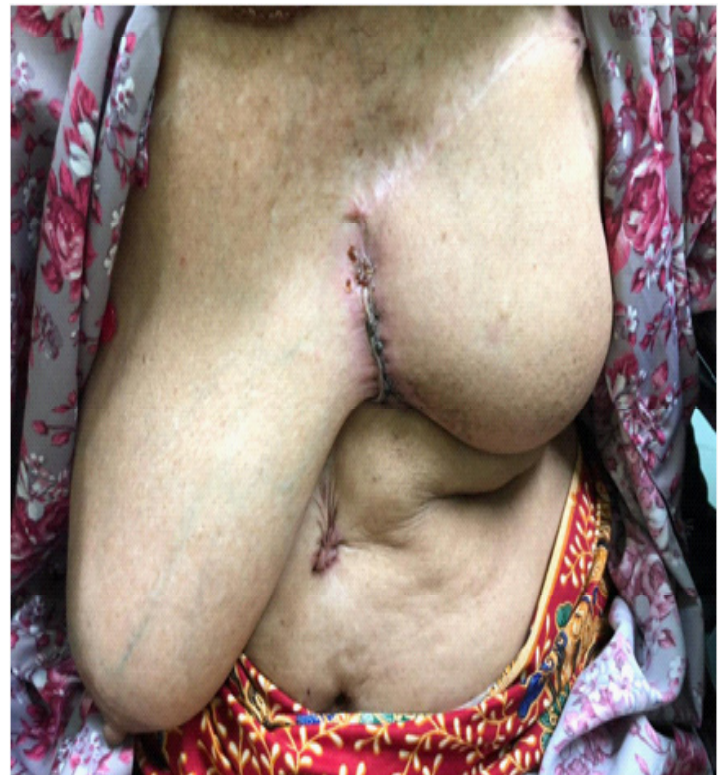

Figure 4: At present in her 9 years follow up

References

1. Group EBCTC. Polychemotherapy for early breast cancer: an overview of the randomised trials. *The Lancet*. 1998; 352(9132): 930-42.
2. Kontani K, Hashimoto S, Murazawa C, Norimura S, Tanaka H, Ohtani M, et al. Metronomic chemotherapy for metastatic breast cancer to prolong time to treatment failure to 12 months or more. *Mol Clin Oncol*. 2013; 1.
3. Kontani K, Hashimoto S-i, Murazawa C, Norimura S, Tanaka H, Ohtani M, et al. Factors responsible for long-term survival in metastatic breast cancer. *World Journal of Surgical Oncology*. 2014; 12(1): 344.
4. Larionov AA. Current Therapies for Human Epidermal Growth Factor Receptor 2-Positive Metastatic Breast Cancer Patients. *Front Oncol*. 2018; 8: 89
5. Hayashi N, Niikura N, Yamauchi H, Nakamura S, Ueno NT. Adding hormonal therapy to chemotherapy and trastuzumab improves prognosis in patients with hormone receptor-positive and human epidermal growth factor receptor 2-positive primary breast cancer. *Breast cancer research and treatment*. 2013; 137(2): 523-31.
6. Kobayashi T, Ichiba T, Sakuyama T, Arakawa Y, Nagasaki E, Aiba K, et al. Possible clinical cure of metastatic breast cancer: lessons from our 30-year experience with oligometastatic breast cancer patients and literature review. *Breast Cancer*. 2012; 19(3): 218-37.
7. Rapiti E, Verkooijen HM, Vlastos G, Fioretta G, Neyroud-Caspar I, Sappino AP, et al. Complete excision of primary breast tumor improves survival of patients with metastatic breast cancer at diagnosis. *J Clin Oncol*. 2006; 24(18): 2743-9.
8. O'Shaughnessy J. Extending Survival with Chemotherapy in Metastatic Breast Cancer. *The Oncologist*. 2005; 10(suppl 3): 20-9.

Manuscript Information: Received: October 14, 2019; Accepted: December 09, 2019; Published: December 27, 2019

Authors Information: Arvind Navaneethkumar¹; Wan Zainira Wan Zain^{2*}; Maya Mazuwin Yahya²

¹Department of Surgery, Hospital Raja Permaisuri Bainun Ipoh, Perak, Malaysia

²Department of Surgery, School of Medical Sciences, Universiti Sains Malaysia Health Campus, Kota Bharu, Kelantan, Malaysia

Citation: Navaneethkumar A, Wan Zain WZ, Yahya MM. Defying death in Breast Cancer. *Open J Clin Med Case Rep*. 2019; 1608.

Copy right statement: Content published in the journal follows Creative Commons Attribution License

(<http://creativecommons.org/licenses/by/4.0>). © **Wan Zain WZ 2019**

About the Journal: Open Journal of Clinical and Medical Case Reports is an international, open access, peer reviewed Journal focusing exclusively on case reports covering all areas of clinical & medical sciences.

Visit the journal website at www.jclinmedcasereports.com

For reprints and other information, contact info@jclinmedcasereports.com