

## Not all fingersticks are reliable! - A case of Artifactual Hypoglycemia

Monisha Kumar\*; Braghadheeswar Thyagarajan; Nairmeen Haller; Michael Morocco

**\*Corresponding Author(s): Monisha Kumar**

Department of Internal Medicine, Cleveland Clinic Akron General, Akron, OH, USA

Email: monishapdk@gmail.com

### Abstract

Hypoglycemia in non-diabetics is uncommon and often unsuspected. Persistent hypoglycemia can have dreadful consequences and is a clinical emergency. Symptoms of hypoglycemia often overlap with symptoms of other medical conditions increasing the difficulty in making the diagnosis. Artifactual hypoglycemia occurs in cases of erroneous low blood glucose measurement in the setting of true normal blood glucose in asymptomatic individuals. Patients with Raynaud's phenomenon can have artifactual hypoglycemia as a result of peripheral vasoconstriction. Warming hands prior to checking finger-stick glucose levels can help avoid errors. Alternately, ear lobes can be used as a site for peripheral stick glucose monitoring in order to minimize erroneous values and associated healthcare expenditure.

### Keywords

hypoglycemia; Raynaud's phenomenon; fingerstick glucose; artifactual hypoglycemia

### Introduction

Persistent hypoglycemia is a clinical emergency that warrants medical attention and evaluation to avoid dreadful consequences. Although severe hypoglycemia is more prevalent in medically treated patients with diabetes and is associated with multifold increase in mortality rate, it remains an uncommon condition among non-diabetic patients [1]. The following report describes a case of falsely low fingerstick glucose values in a patient with Raynaud's Phenomenon leading to delayed diagnosis and expensive workup.

### Case Report

An 88-year-old female with a past medical history of atrial fibrillation, coronary artery disease, congestive heart failure, Raynaud's phenomenon and severe pulmonary hypertension presented to the emergency department for evaluation of recurrent pre-syncopal episodes. She reported intermittent lighthead-

edness and generalized weakness for 1 week duration. Her review of systems was negative for fever, chills, chest pain, shortness of breath, palpitations, auditory symptoms, aura or seizures. Her vitals on presentation included blood pressure of 99/59 mmHg, heart rate of 62 per minute and oxygen saturation over 94 percent on room air. She remained afebrile and pertinent physical exam findings included irregular heart rhythm, and purplish hue in all digits. As part of her initial evaluation, a finger stick blood glucose reading was checked due to continued lightheadedness and it revealed a reading of less than 50 mg/dL. She was subsequently treated with intravenous dextrose 50% 25 grams with no significant improvement in symptoms and admitted for further evaluation.

The patient had undergone programmed finger-stick glucose monitoring on the medical floor due to concern of the hypoglycemia being the cause of her pre-syncopal episodes. Her complete blood count resulted unremarkable with hemoglobin 11.8 (11.7-14.7) g/dL, platelet 275 (150-370) thou/cmm, and white blood cell count 5.2(4.4-9.7) tho/cmm. Even though the patient was eating an adequate diet, the values of her finger stick glucose ranged from 50-60 mg/dL, requiring multiple intravenous dextrose treatments. Her Hemoglobin A1c was within normal limits. The hypoglycemic evaluation included plasma C-peptide, proinsulin, plasma Insulin level, and serum glucose level test during a hypoglycemic episode with low fingerstick glucose. Curiously, her simultaneous serum blood glucose during low fingerstick glucose was higher and within normal range, and her C-peptide, proinsulin, plasma Insulin levels were unremarkable.

Following a review of her home medications, which included amlodipine, furosemide, extended release metoprolol succinate, and irbesartan, polypharmacy induced orthostatic hypotension was concluded to be the etiology of her recurrent presyncopal episodes. This was confirmed with an improvement in her symptoms following down-titration of her blood pressure lowering medications. Given the persistent hypoglycemia in a non-diabetic individual, she was further evaluated. A cosyntropin stimulation test revealed normal adrenal gland function. The patient did not have any neurogenic or neuroglycopenic symptoms and was essentially asymptomatic after her anti hypertensive medication adjustments, even during episodes of low glucose readings by finger-stick. A review of her labs revealed that her serum blood glucose value from intravenous blood draws were ranging between 90-120 mg/dL (Figure 1) Further, the fingerstick blood glucose after administration of intravenous dextrose 50% 25 grams were noted to improve fingerstick values only minimally ranging between 15-30 mg/dL leading to multiple dextrose 50% intravenous administrations.

Her serum glucose values were normal, and did not correlate with any of the "low" finger-stick blood glucose levels. Given her Raynaud's disease and intermittent purplish hues at bilateral fingertips through the course of hospital stay, there was a concern for falsely low finger stick glucose values from vasoconstriction. Hence, decision made to perform hand warming measures prior to fingerstick glucose testing. Her fingerstick blood glucose values before and after hand warming were 48 and 81 mg/dL respectively, and simultaneous serum glucose was 96 mg/dL. Thus, from that point, finger-stick glucose testing was done only after measures to warm her hands and these were normal closely correlating with simultaneous serum glucose levels. It was then concluded that her low finger-stick blood glucose values were due to the vasoconstrictive effect from her Raynaud's phenomenon.

## Discussion

In healthy individuals, the normal serum glucose level ranges between 60 to 100 mg/dL and hypoglycemia represents a clinical syndrome with symptomatic low blood glucose concentration resulting from impaired physiological regulatory mechanisms [2]. Hypoglycemia is common among individuals with diabetes who are on insulin or anti-diabetic agents, but uncommon among non-diabetic individuals, and warrants further evaluation. Irrespective of diabetes status, the overall prevalence of hypoglycemia remains as high as 10.1% in intensive care unit setting and 3.5% in non-ICU setting, thus emphasizing that early identification of erroneous test results is substantial [3].

Hypoglycemia can present with non-specific symptoms that overlap with other conditions as seen in our patient. This creates a challenging diagnostic situation. Symptoms are broadly categorized as neurogenic versus neuroglycopenic [4]. Neurogenic symptoms including tremor, anxiety or palpitations are catecholamine release-mediated, whereas paresthesia, hunger, sweating is acetylcholine release-mediated. Neuroglycopenic symptoms encompasses confusion, syncope, seizures, cognitive impairment or even brain death in severe cases [4]. Hypoglycemia in nondiabetic individuals warrants further extensive evaluation for conditions including endogenous, accidental, or surreptitious hyperinsulinism and other endocrinological derangements depending on the clinical scenario. Thus, understanding the nuances in fingerstick glucose interpretation and early identification of errors plays a crucial role in averting unnecessary expenditure.

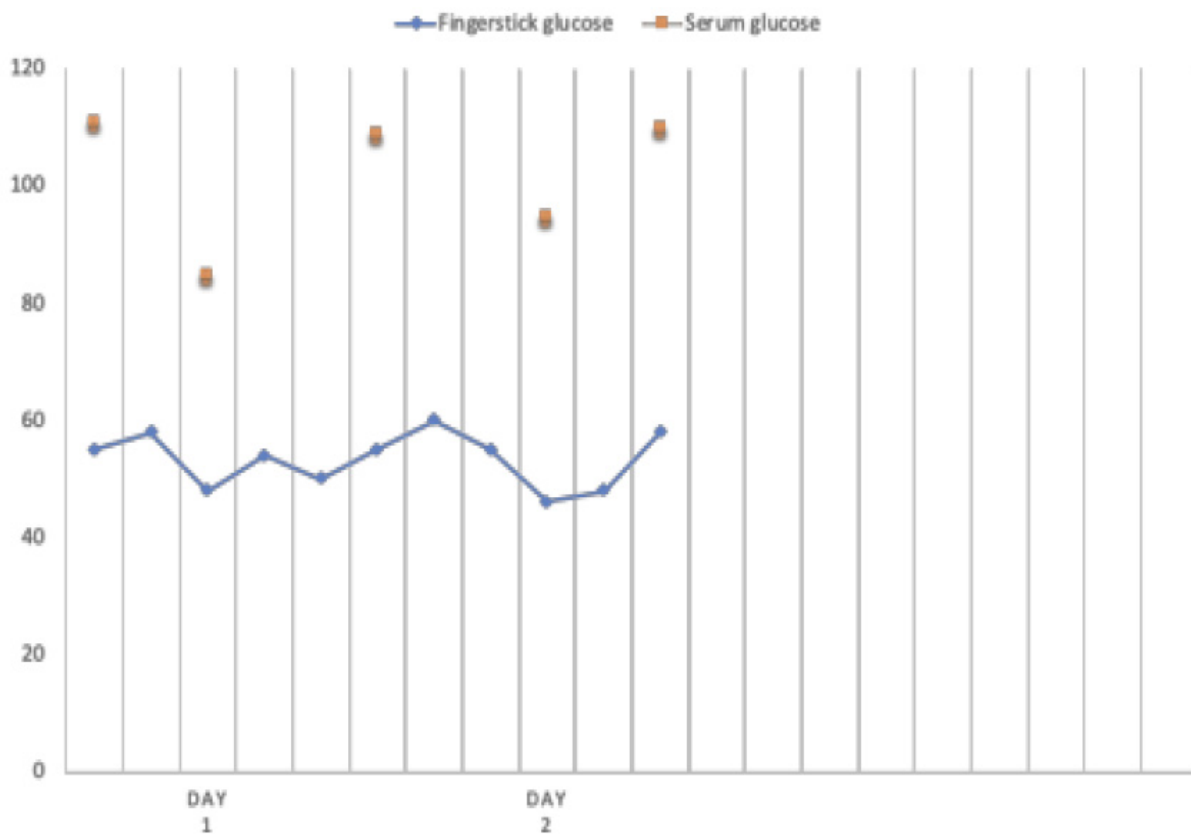
The term artifactual hypoglycemia represents erroneous low blood glucose measurement in the setting of true normal blood glucose levels in asymptomatic individuals [5,6]. Blood glucose readings that are discordant between the finger-sticks and the serum blood glucose measurement, as seen in this case, may be caused by peripheral vasoconstriction. Patients with Raynaud's phenomenon have decreased capillary blood flow, which may yield false low capillary blood glucose values. On review of the literature, only six case reports describing false low finger-stick blood glucose levels in association with Raynaud's phenomenon, scleroderma and acrocyanosis, and Eisenmenger syndrome and acrocyanosis have been reported. [7-9]. It is believed that this effect is underreported, and the actual occurrence of artifactual hypoglycemia in clinical practice could be higher given that the prevalence of Raynaud's is as high as 4.85% in the general population.

## Conclusion

In conclusion, in cases of discordance between finger-stick glucose values and serum glucose values, consideration should be given to a history of Raynaud's phenomenon [7,9]. Warming hands prior to fingerstick glucose testing may help minimize errors and inconsequential evaluation, since vasodilation with warming counteracts the vasoconstrictive effects of Raynaud's phenomenon [6,9,10]. There are no current evidence based recommendations on the hand warming method available on literature, but in this case, patient washed her hands in lukewarm water for 3-5 minutes prior to testing. Alternately, using ear lobe pricks for measuring blood glucose testing would improve accuracy of readings [9,10]. Consideration of blood sampling strategy in patients with Raynaud's phenomenon with suspected effects of hypoglycemia

may avoid costs and risks associated with unnecessary extensive workup.

## Figures



**Figure 1:** Finger-stick glucose values lower than simultaneous serum glucose values in a patient with Raynaud's phenomenon.

## References

1. Cryer PE. Severe hypoglycemia predicts mortality in diabetes. *Diabetes Care*. 2012; 35[9]: 1814-6.
2. Service FJ. Hypoglycemic disorders. *N Engl J Med*. 1995; 332[17]: 1144-52.
3. Cook CB, Kongable GL, Potter DJ, Abad VJ, Leija DE, Anderson M. Inpatient glucose control: a glycemic survey of 126 U.S. hospitals. *J Hosp Med*. 2009; 4[9]: E7-E14.
4. Seaquist ER, Anderson J, Childs B, Cryer P, Dagogo-Jack S, Fish L, Heller SR, Rodriguez H, Rosenzweig J, Vigersky R. American Diabetes Association; Endocrine Society. Hypoglycemia and diabetes: a report of a workgroup of the American Diabetes Association and the Endocrine Society. *J Clin Endocrinol Metab*. 2013; 98[5]: 1845-59.
5. Tarasova VD, Zena M, Rendell M. Artfactual hypoglycemia: an old term for a new classification. *Diabetes Care*. 2014; 37[5]: e85-6.
6. Horwitz DL. Factitious and artfactual hypoglycemia. *Endocrinol Metab ClinNorth Am*. 1989; 18[1]: 203-10.
7. Bishay RH, Suryawanshi A. Artfactual Hypoglycemia in Systemic Sclerosis and Raynaud's Phenomenon: A Clinical Case Report and Short Review. *Case Rep Endocrinol*. 2016; 2016: 73909-27.
8. Nourrisson C, Batisse M, Sapin V, Bouvier D. [Pseudo-hypoglycemia and hyperleukocytosis: a case report]. *Ann Biol Clin [Paris]*. 2010; 68[4]: 490-4.

9. Garner R, Kumari R, Lanyon P, Doherty M, Zhang W. Prevalence, risk factors and associations of primary Raynaud's phenomenon: systematic review and meta-analysis of observational studies. *BMJ Open*. 2015; 5[3]: e006389.
10. Lee KT, Abadir PM. Failure of Glucose Monitoring in an Individual with Pseudohypoglycemia. *J Am Geriatr Soc*. 2015 ;63[8]: 1706-8.

**Manuscript Information:** Received: April 24, 2019; Accepted: December 02, 2019; Published: December 27, 2019

**Authors Information:** Monisha Kumar<sup>1\*</sup>; Braghadheeswar Thyagarajan<sup>2</sup>; Nairmeen Haller<sup>1</sup>; Michael Morocco<sup>1</sup>

<sup>1</sup>Department of Internal Medicine, Cleveland Clinic Akron General, Akron, OH, USA

<sup>2</sup>Department of Critical Care Medicine, Wake Forest Baptist Medical Center, Winston Salem, NC, USA

**Citation:** Kumar M, Thyagarajan B, Haller N, Morocco M. Not all fingersticks are reliable! - A case of Artifactual Hypoglycemia. *Open J Clin Med Case Rep*. 2019; 1606.

**Copy right statement:** Content published in the journal follows Creative Commons Attribution License (<http://creativecommons.org/licenses/by/4.0>). © **Kumar M 2019**

**About the Journal:** Open Journal of Clinical and Medical Case Reports is an international, open access, peer reviewed Journal focusing exclusively on case reports covering all areas of clinical & medical sciences.

Visit the journal website at [www.jclinmedcasereports.com](http://www.jclinmedcasereports.com)

For reprints and other information, contact [info@jclinmedcasereports.com](mailto:info@jclinmedcasereports.com)