

## Ultrasound to the rescue: Unveiling a rare cause of dysphagia in adults

Khandelwal Ayush\*; Jain Swarna; Katyan Amit

**\*Khandelwal Ayush**

Department of Radiodiagnosis, VMMC and Safdarjung Hospital, New Delhi, India

Email: ayush7khandelwal@gmail.com

### Abstract

The purpose of the case report is to highlight the role of ultrasound in the evaluation of oro-pharyngeal dysphagia and report a case of vallecular cyst as a mimicker of laryngeal carcinoma in an elderly female patient.

**Results:** Barium swallow showed a well defined filling defect with sharp margins on the right side of the larynx. High resolution ultrasound showed a well defined anechoic cystic lesion in the base of tongue region on the right side suggestive of vallecular cyst which was confirmed on MRI and histopathology.

**Conclusion:** Transcervical ultrasound is an important modality in the assessment at the base of the tongue and vocal cord lesions. Vallecular cyst although rare, should be kept in the differential diagnosis of oropharyngeal dysphagia in an elderly female patient.

### Keywords

ultrasound; carcinoma; histopathology; vallecular cyst

### Introduction

The usual differential diagnosis for oropharyngeal dysphagia in an elderly patient can be classified into mechanical or non-mechanical etiologies. Mechanical causes of oropharyngeal dysphagia include oesophageal malignancies and esophagitis. Non-mechanical causes of oropharyngeal dysphagia are scleroderma, achalasia cardia and diffuse esophageal spasm. Unusual etiologies of dysphagia in elderly population are a thyroid mass compressing the cervical esophagus, metastatic adenopathy, large cervical osteophytes and laryngeal cysts.

Vallecular cysts are considered rare in the elderly population with an incidence of 1 in 1250 to 1 in 4200 in the general population. Although most cases of vallecular cysts are asymptomatic and incidentally

detected during intubation. In some cases, vallecular cysts may cause symptoms namely change in voice, dysphagia, odynophagia, or dyspnea [3,4]. These clinical symptoms closely resembles that of carcinoma of the larynx and pose an important diagnostic challenge for the clinician. We report an elderly female patient complaining of oropharyngeal dysphagia, who was referred to us for a barium swallow examination. In view of the progressive dysphagia and the age of the patient, the clinical team suspected a laryngeal malignancy despite normal laryngeal findings during indirect laryngoscopy. High resolution ultrasound showed a vallecular cyst which was confirmed on MRI. The purpose of the report is to highlight the role of transcervical ultrasound in the diagnosis of vallecular cyst and differentiating it with carcinoma larynx.

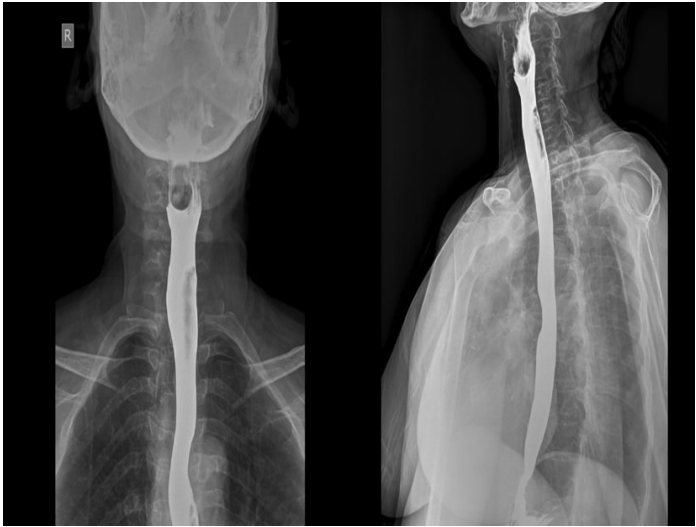## Case Report

A sixty five year old female patient presented to the oto-rhino-laryngology department with the complaint of dysphagia to solid foods since the past six months. Indirect laryngoscopy showed a suspicious lesion in the right vallecular region. Based on age, clinical history and examination, a suspicion of laryngeal malignancy was considered. The patient was referred for a barium swallow examination.

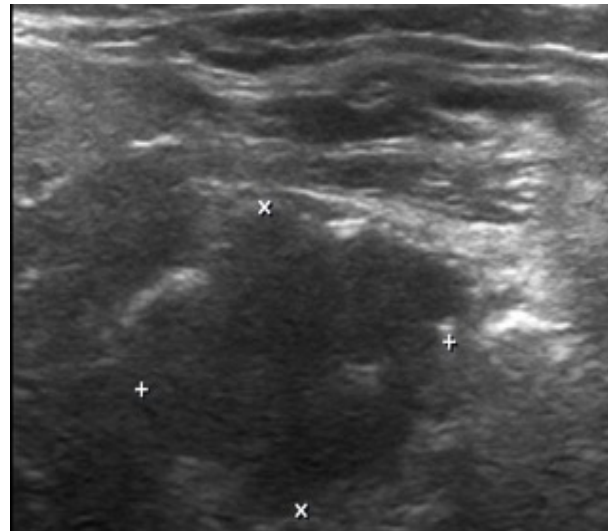
Barium swallow examination was performed by us which revealed a well defined filling defect with sharp margins on the right side of the larynx at the level of third and fourth cervical vertebra (Figure 1). For further characterization of the lesion, a high resolution transcervical ultrasound was performed on a Philips IU 22 scanner using a high frequency transducer (5-17 MHZ). Ultrasound showed a well defined anechoic cystic lesion in the base of tongue region on the right side measuring approximately 17 x 14 mm in size. Few tiny echogenic foci were noted within the internal component of the lesion (Figure 2). Vocal cords were normal in morphology and mobility. Rest of the examination of the neck was normal. Based on the location and ultrasound characteristics of the lesion, a diagnosis of vallecular cyst was arrived at. MRI of the neck was performed for further confirmation of the diagnosis. MRI examination showed a well defined cystic lesion in the right vallecula which followed fluid signal intensity on T1W and T2W sequences (Figure 3).

Based on the imaging findings of a vallecular cyst, an elective surgical laryngoscopic excision of vallecular cyst was performed under general anaesthesia (Figure 4). There were no intra operative or post operative complications and the patient reported near complete resolution of symptoms following the procedure. Histopathological examination of the surgical specimen showed a cyst lined by stratified squamous epithelium with follicular lymphoid tissue, consistent with laryngeal cyst (Vallecular cyst). There was no evidence of any ectopic thyroid tissue within the lesion.

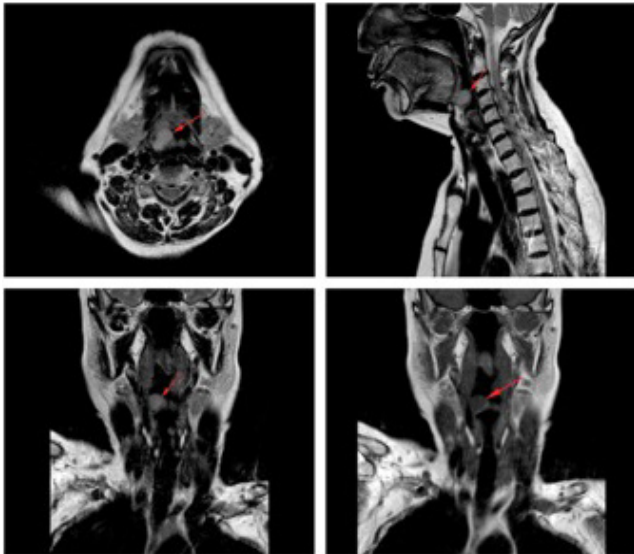
The patient was asymptomatic when she she visited the out patient department one month after the surgery. A written informed consent was obtained from the patient that the data concerning her diagnosis and management may be submitted for publication. The patient was informed that her identity will not be revealed in any manner.



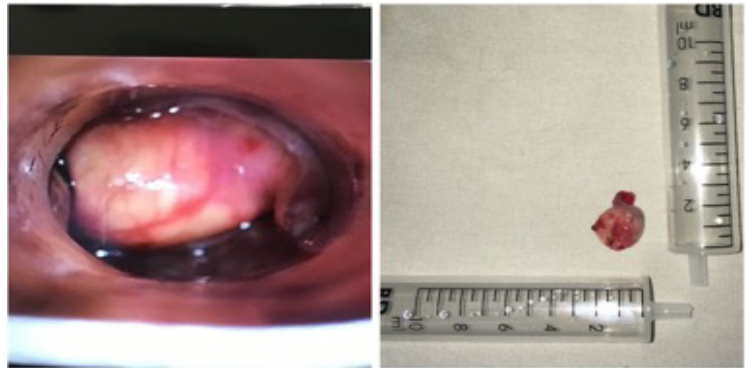
**Figure 1:** Barium swallow of the patient shows a filling defect at the level of second and third cervical vertebra with sharp inferior and left lateral margins. The rest of the oesophagus was normally opacified with contrast. Imaging signs of malignancy were conspicuous by its absence.



**Figure 2:** High resolution ultrasound of the patient shows a well defined anechoic cystic lesion in supraglottic portion of larynx showing posterior acoustic enhancement.



**Figure 3:** T2 (axial (a), sagittal (b) and coronal (c)) and T1w coronal images of the same patient showing a well defined lesion in the right vallecula showing T1W hypointense and T2W hyperintense signals. Associated mild airway compression is also noted.



**Figure 4:** Laryngoscopic visualisation of the vallecular cyst under microscope and excised vallecular cyst of size 2 x 2 cm.

## Discussion

Vallecular cysts, also called epiglottic mucus retention cysts at the base of the tongue, occur due to trauma or inflammation induced obstruction and subsequent dilatation of a mucous gland or lingual tonsillar crypts [1,2].

Ductal cysts are the most common laryngeal cysts and occur most frequently at the true vocal fold. Other sites of ductal cysts include the epiglottis and vallecula [3,4]. Vallecular cysts resembling tonsillar crypts due to associated lymphoid tissue have been separately classified as lymphoepithelial cysts and may also occur in the aryepiglottic fold, vestibule and piriform sinus [3].

Infants with vallecular cysts are considered to be at risk of airway obstruction and death [2]. Therefore, all such cysts in infants and children should be removed surgically by marsupialization via CO2 laser or electrocautery [1,2,7].

In adults, vallecular cysts are generally asymptomatic. Nearly two-thirds of vallecular cysts are asymptomatic and are diagnosed incidentally on routine laryngeal examination [3]. In symptomatic individuals, these cysts typically presents with misleading clinical symptoms which often mimic a laryngeal malignancy. The peak incidence is in the fifth decade of life, and the majority of cysts occur in men [2,3,5]. Ultrasound of the larynx can elegantly demonstrate the cystic nature of such lesions and confidently exclude a laryngeal malignancy.

The surgical management options for the treatment of vallecular cysts include watchful monitoring, cyst aspiration, marsupialization, surgical debulking, microdebrider marsupialization or laser excision [2,8-12].

In the case described here, the clinical and imaging findings were suggestive of a vallecular cyst. Although rare, vallecular cysts should be considered in the workup of dysphagia.

## Conclusion

We report a an elderly patient with a confounding clinical presentation of a malignancy which was diagnosed as a benign vallecular cyst based on ultrasound and MRI evaluation. Our report highlights the importance of transcervical ultrasound in the diagnosis of the base of the tongue and vocal cord lesions. Although, vallecular cysts are fairly rare in the adult population, our report purports to consider a differential diagnosis of a vallecular cyst in a patient presenting with oro-pharyngeal dysphagia.

## References

1. G. Berger E, Averbuch K, Zilka R, Berger, Ophir D. Adult vallecular cyst: thirteen-year experience. *Otolaryngology*. 2008; 138: 321–327.
2. Gutiérrez JP, Berkowitz RG, Robertson CF. Vallecular cysts in newborns and young infants. *Pediatric Pulmonology*. 1999; 27: 282–285.
3. Arens C, Glanz H, Kleinsasser O., "Clinical and morphological aspects of laryngeal cysts," *European Archives of Oto-Rhino-Laryngology*, vol. 254, no. 9-10, pp. 430–436, 1997.
4. DeSanto LW, Devine KD, Weiland LH, Cysts of the larynx—classification. *Laryngoscope*. 1970; 80: 145–176.
5. Mason DG, Wark KJ. Unexpected difficult intubation. Asymptomatic epiglottic cysts as a cause of upper airway obstruction during anaesthesia. *Anaesthesia*. 1987; 42: 407–410.
6. Rivo J, Matot I. Asymptomatic vallecular cyst: airway management considerations. *Journal of Clinical Anesthesia*. 2001; 13: 383–386.
7. Leuin S, Cunningham M, Volk MS, Hartnick c. Transhyoid approach to excision of recurrent vallecular pseudocysts. *Laryngoscope* 2008; 118: 124–127.

8. KU A. Vallecular cyst: report of four cases--one with co-existing laryngomalacia. J Laryngol Otol. 2000; 114: 224-226.
9. Leibowitz JM, et al. Diagnosis and treatment of pediatric vallecular cysts and pseudocysts. Int J Pediatr Otorhinolaryngol. 2011; 75: 899-904.
10. Chen EY, et al. Transoral approach for direct and complete excision of vallecular cysts in children. Int J Pediatr Otorhinolaryngol. 2011; 75: 1147-1151.
11. Pagella F, et al. Transoral power-assisted marsupialization of vallecular cysts under local anesthesia. Laryngoscope. 2013; 123: 699-701.
12. Liu X, et al. [Application of electric coagulation treatment via bronchoscopy in the management of congenital vallecular cyst in children. Zhonghua Er Ke Za Zhi. 2013; 51: 846-848.

**Manuscript Information:** Received: March 18, 2019; Accepted: July 11, 2019; Published: July 15, 2019

**Authors Information:** Khandelwal Ayush\*; Jain Swarna; Katyan Amit  
Department of Radiodiagnosis, VMMC and Safdarjung Hospital, New Delhi, India

**Citation:** Ayush K, Swarna J, Amit K. Ultrasound to the rescue: Unveiling a rare cause of dysphagia in adults. Open J Clin Med Case Rep. 2019; 1562.

**Copy right statement:** Content published in the journal follows Creative Commons Attribution License (<http://creativecommons.org/licenses/by/4.0>). © Ayush K 2019

**About the Journal:** Open Journal of Clinical and Medical Case Reports is an international, open access, peer reviewed Journal focusing exclusively on case reports covering all areas of clinical & medical sciences.

Visit the journal website at [www.jclinmedcasereports.com](http://www.jclinmedcasereports.com)

For reprints and other information, contact [info@jclinmedcasereports.com](mailto:info@jclinmedcasereports.com)