

## Idiopathic granulomatous mastitis mimicking inflammatory carcinoma breast: Case report and literature review

Hemant Sharma\*, Shivani Prashar

**\*Hemant Sharma**

Department of Pathology, Government Hospital, Danapur Cantt, Patna, Bihar, India

Email: hemant1303@gmail.com

### Abstract

Idiopathic Granulomatous Mastitis is an uncommon rare benign chronic breast disease with unknown etiology, multi factorial pathogenesis, unpredictable clinical behavior and response to the treatment and remains a diagnosis of exclusion. Usually, Idiopathic Granulomatous Mastitis IGM presents with overlying skin erythema, sinus and regional lymphadenopathy mimicking Inflammatory Breast carcinoma. Clinical and Imaging findings of IGM are similar to various other benign inflammatory granulomatous diseases and inflammatory Carcinoma Breast. In more 50% cases, initial diagnosis of IGM is Breast carcinoma. Treatment modality differs for IGM, other benign causes of granulomatous mastitis and Breast cancer. Correct and Timely diagnosis of IGM is important in saving unnecessary mastectomy and mental agony to the patient, to prevent flare up of inflammatory mastitis and prevent long term side effects of corticosteroids. We report a rare case of Idiopathic Granulomatous Mastitis, clinico-radiologically mimicking as inflammatory carcinoma Breast, to create awareness among clinical fraternity and avoid unnecessary mastectomies.

### Keywords

mastitis; idiopathic granulomatous mastitis; inflammatory carcinoma breast

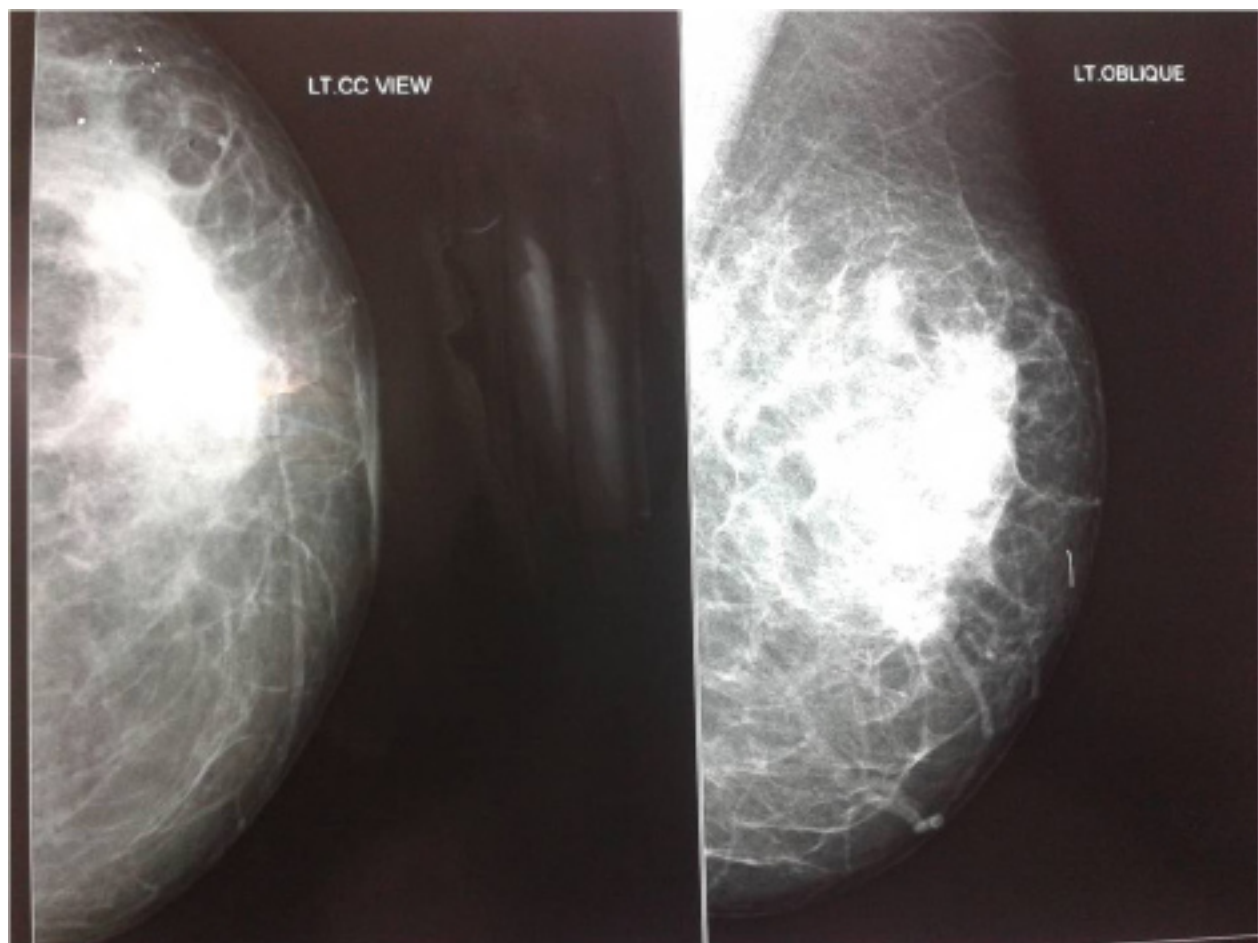
### Introduction

Idiopathic Granulomatous Mastitis (IGM), also known as Idiopathic Granulomatous Lobular Mastitis (IGLM) is an uncommon rare recurrent benign chronic breast disease with complex etiology, multi factorial pathogenesis, unpredictable clinical behavior and response to the treatment [1-3]. IGM cases have been reported very rarely as it remains a diagnosis of exclusion highlighting its Clinical, Radiological and Histopathological similarity to other benign Granulomatous diseases of Breast like Tuberculosis, Sarcoidosis, Wegner's Granulomatous, Foreign body reaction, Giant cell arteritis, Polyarteritis Nodosum, various Mycotic infections and Periductal mastitis on one hand and Malignant entities like Inflammatory Breast carcinoma on other hand [2-6,14]. According to Bani-Hani et al, up to 50% of IGM of cases can mimic

Breast carcinoma on presentation [3]. Mainstay of treatment of IGM is conservative with corticosteroids and immunosuppressive therapy [3,6,12]. We present a very rare case clinico-radiologically diagnosed as a case of Inflammatory Breast carcinoma but histopathologically diagnosed as IGM and saved unnecessary mastectomy and chemo-radiotherapy to the patient.

## Case Report

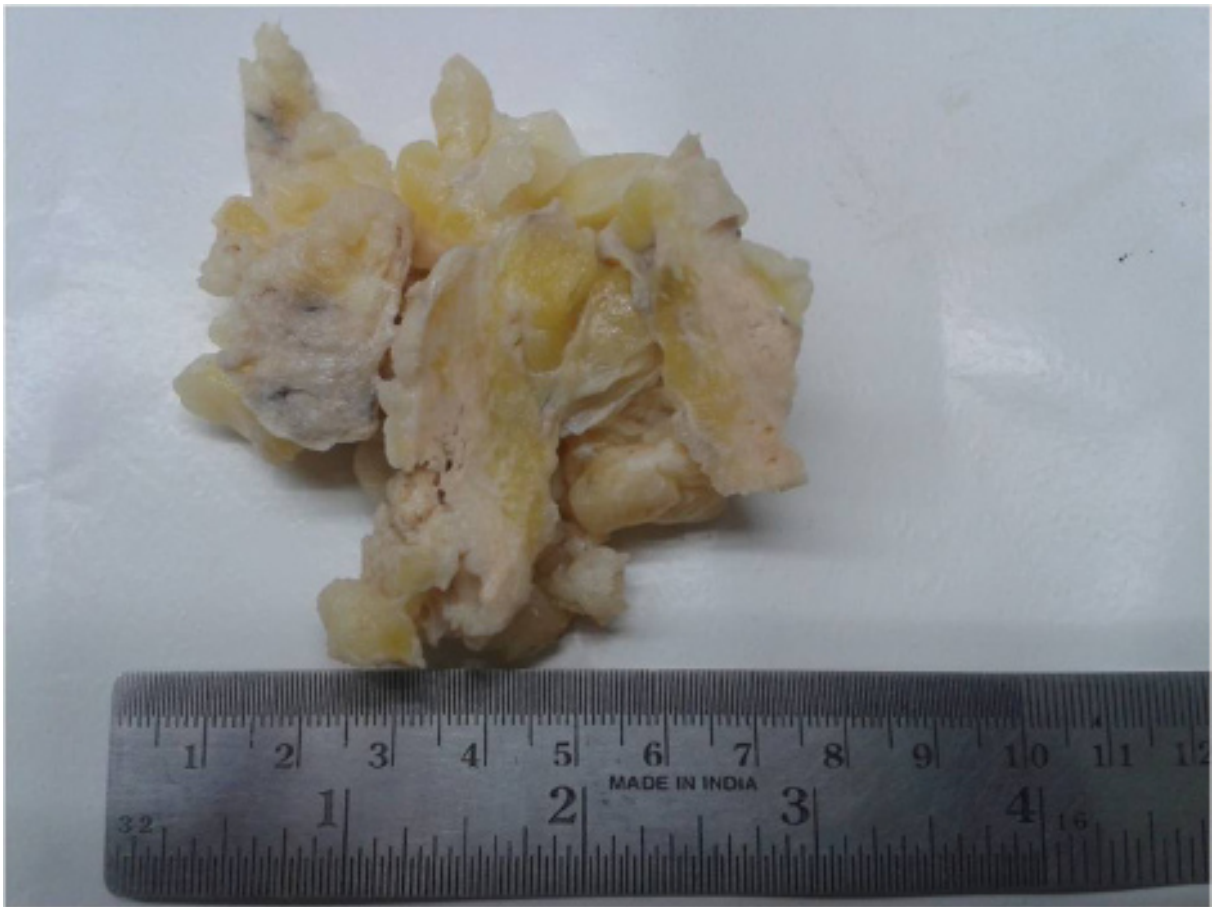A 30 years old Parous woman presented to outpatient department with two-month history of progressively enlarging tender lump in Left breast. On examination, a firm to hard lump was palpated in Left Breast measuring 5.0cm x 3.0cm in upper outer quadrant. Skin overlying lump was normal. No Nipple retraction or nipple discharge noticed. No axillary lymph nodes were palpable. Right Breast was normal. Her systemic examination and all routine investigations were normal. She did not give any recent or past history of systemic illness, Infectious disease or Tuberculosis. She had two children, age 5 years and 10 months respectively and she was not on Oral contraceptive pills. At the time of presentation, she had discontinued breast feeding for 4 months. There was no history of breast cancer in patient or in her family. She also denied any history of alcohol consumption, tobacco or substance abuse. No history of any long term medication or drug allergy was reported.



**Figure 1:** Mammography shows ill defined area of increased density in Superolateral part of Breast with areolar thickening

Based on above findings, she was worked up for breast lump presuming it to be a inflammatory mastitis. Her mammography revealed an ill defined area of increased density with slight areolar skin thickening and probable diagnosis of Inflammatory Carcinoma Breast was given (Fig 1). Fine Needle Aspiration Cytology of the lump was attempted which did not yield any conclusive report except few inflammatory cells comprising of lymphocytes and neutrophils. Because of increasing tenderness, patient was started on broad spectrum antibiotics and kept under observation.

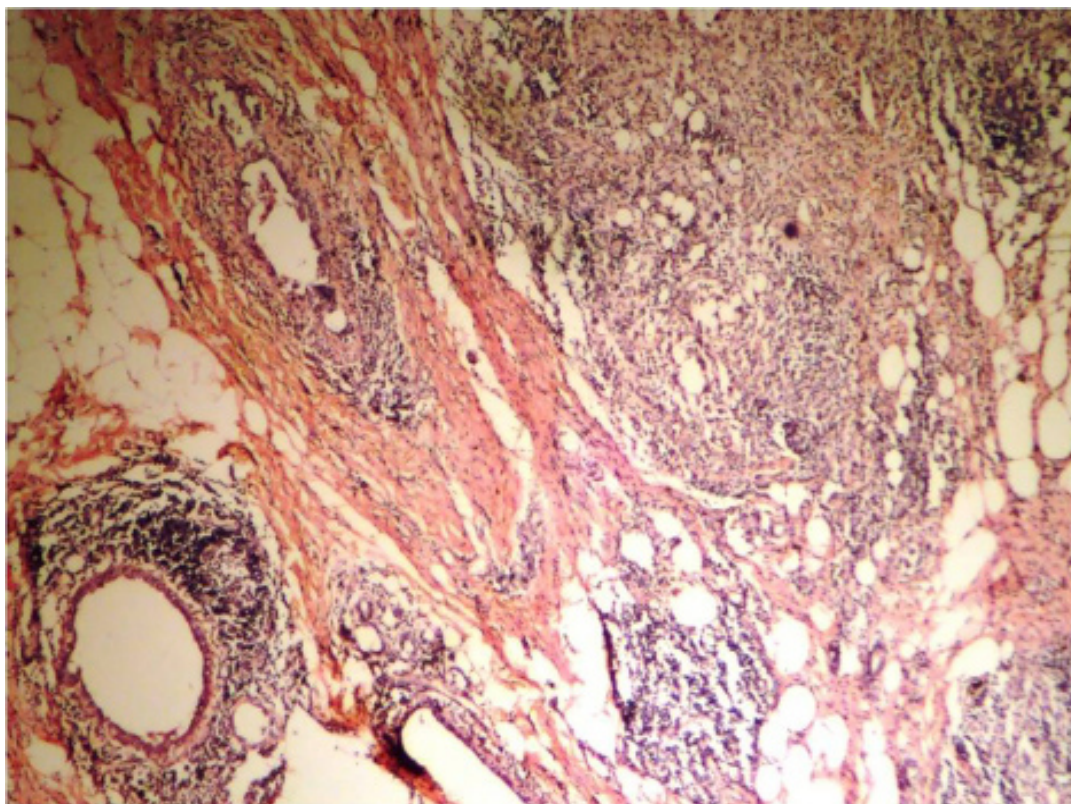
After a course of broad spectrum antibiotics, patient reported back with increased size of lump but reduced tenderness. Because of progressively increasing size of the lump, patient was taken up for breast conservative surgery. We received 10% formalin fixed wide local excision specimen of breast lump measuring 7.0cm x 6.0cm x 2.0cm with surrounding fibro fatty tissue and areas of normal breast (Fig 2).



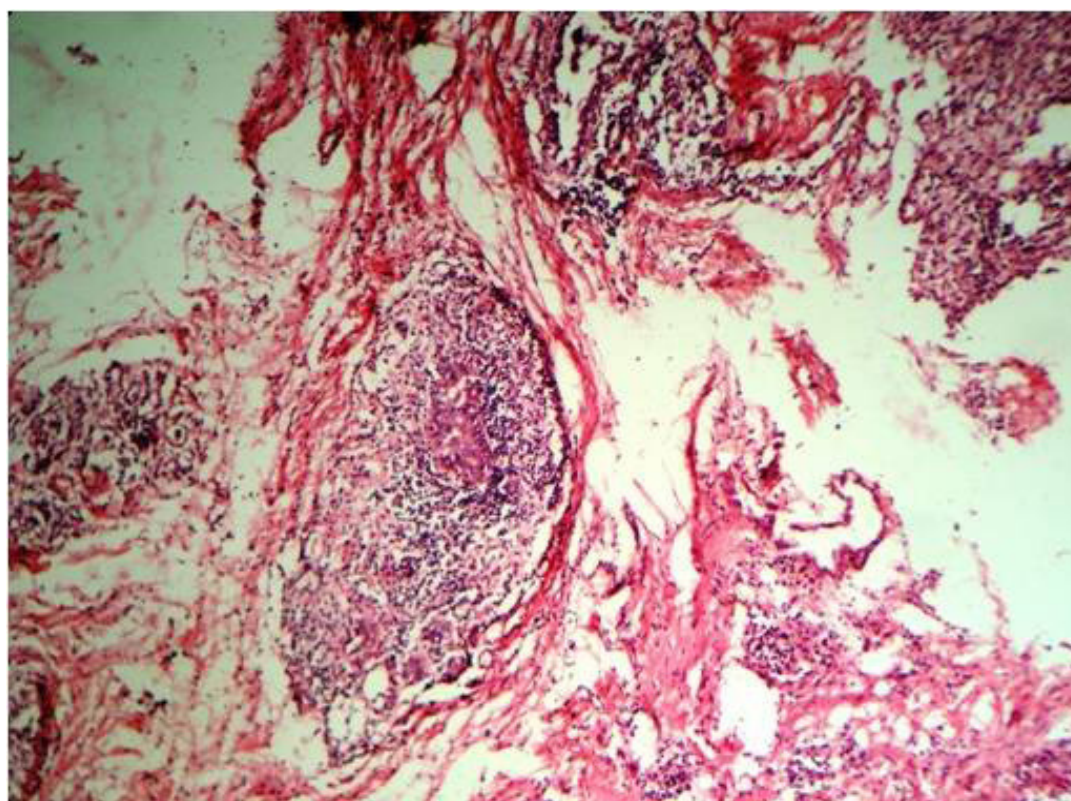
**Figure 2:** Wide local excision of Breast Lump with surrounding fibrofatty normal breast tissues

Specimen was hard to cut and there was no abscess, cystic areas or necrotic area. Few punctuate area of hemorrhage also seen. All the sections were stained with Hematoxylin and Eosin stain. Histopathological examination of stained slides revealed polymorphous chronic inflammatory infiltrate surrounding lobules comprising predominantly of lymphocytes, plasma cells, macrophages, epithleoid like Histiocytes and multinucleate type giant cells suggestive of granulomatous process. No caseation or necrosis seen (Fig 3-5).



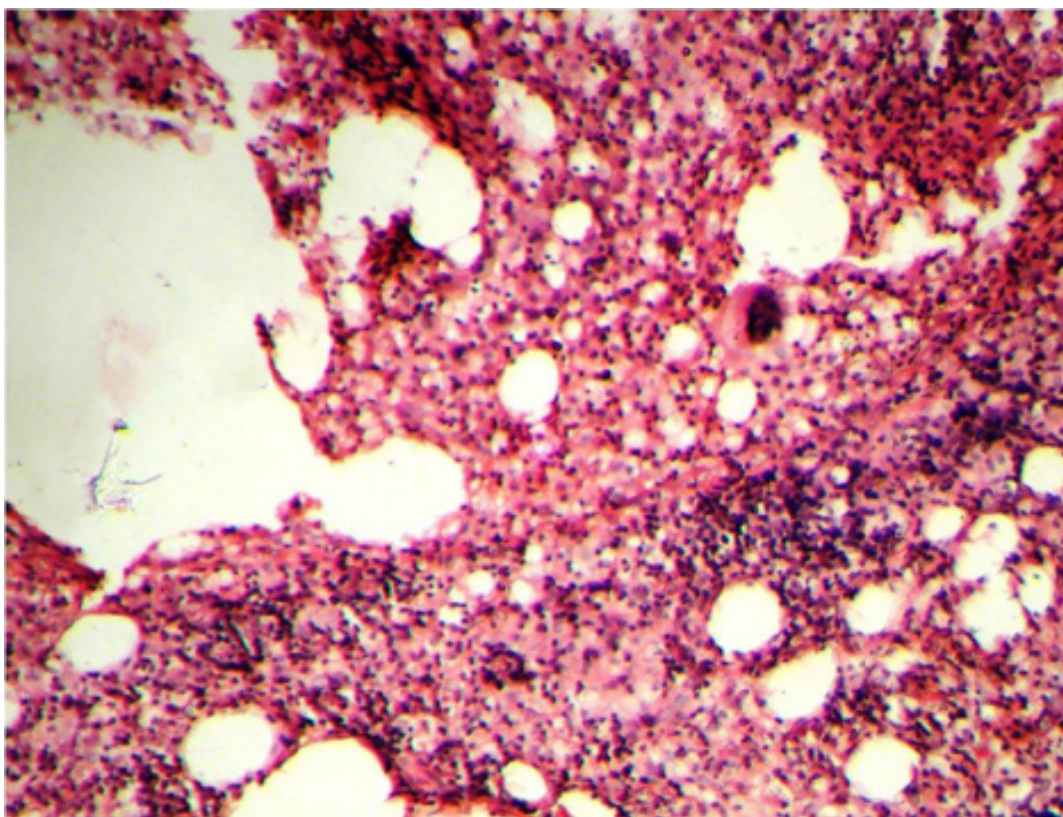


**Figure 3:** Wide local excision of Breast Lump with surrounding fibrofatty normal breast tissues



**Figure 4:** Histopathology of Breast Lump showing lobular destruction by granulomatous inflammation (Haematoxylin and Eosin x100)





**Figure 5:** Granulomatous Inflammation with multinucleate giant cells, Epithelioid cells, Neutrophils and Lymphocytes. No caseous necrosis (Haematoxylin and Eosinx400)

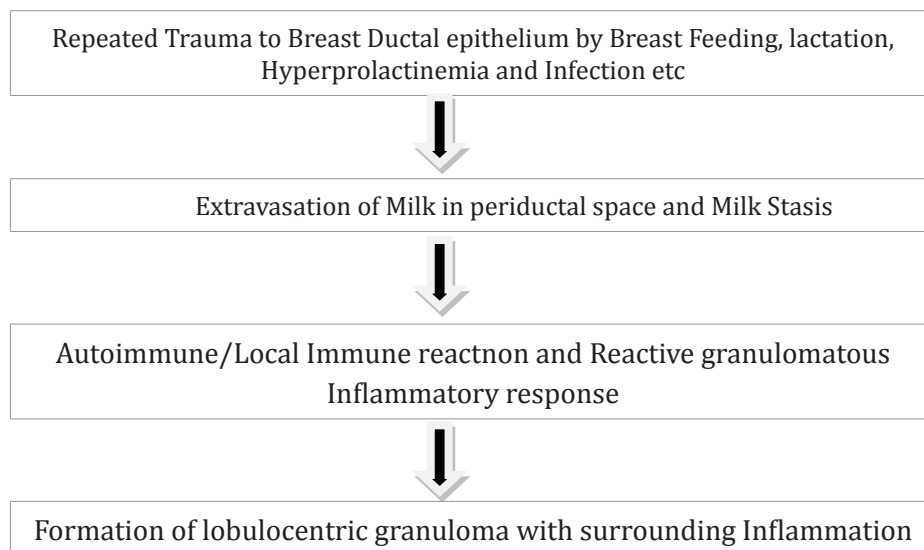
There was no evidence of malignancy. Slides stained with Gram Stain, Ziel-Nielson stain and Periodic Acid Schiff (PAS) stain were negative for any bacterial, tubercular or fungal etiology. Based on the above findings, a diagnosis of Idiopathic Granulomatous mastitis was offered. Patient was subsequently treated with low dose oral corticosteroids (Tablet Prednisolone 0.8mg/kg) with gradual tapering dosage for six months to prevent any recurrence. Her swelling completely subsided gradually and after one year post surgery, patient has not reported any recurrence of symptoms.

## Discussion

IGM was first reported and described as lobulocentric granulomatous inflammation of Breast by in 1972 Kessler and Wollock [1]. Majority of IGM cases reported so far are women in 3rd-4th decade of life (Age range 11-83 yrs) with recent history of lactation and child birth between 2 months-15 years since last delivery [2-4,10-14]. In our case, Patient was middle aged woman with history of childbirth 10 months back. Presently she was breastfeeding her 10 months old baby.

Patients usually present with unilateral (Bilateral in 25% cases) ill-defined indurated breast lump (tender in 25% cases) [1,3-6]. In long standing cases, skin overlying lump develops erythema, induration, *pau d orange*, fistulae, abscess, sinus and sometimes nipple inversion with axillary lymphadenopathy in 15% cases simulating breast carcinoma [2-6]. According to Lei at al., more than 50% IGM cases initially presented as breast carcinoma [9]. Multi factorial etiological agents have been implicated in the pathogenesis of IGM like Pregnancy, Lactation, Hyperprolactinemia, Alpha 1-antitrypsin deficiency, Oral contraceptive

use (0-33% cases) [3,4,10] Corynebacterium Infection and smoking. [2-10,14] Despite so many possible theories postulated since 1972, exact etiology and pathogenesis of IGM is unclear. Based on literature review, a Hypothetical pathogenesis is proposed by various studies shows casual association between development of IGM and hormonal imbalance, autoimmunity, trauma and milk stasis due to various above mentioned multi factorial etiological agents (Fig 5) [1-8,12]. Autoimmunity has been postulated as one of the mechanism of development of IGM because of clinical similarity to Granulomatous Thyroiditis, Granulomatous Orchitis and Granulomatous Prostatitis and therapeutic response to oral corticosteroids and immunosuppressive therapy [2,6,10]. In our case, IGM developed after patient had stopped breast feeding for four months.



**Figure 6:** Hypothetical Multifactorial Pathogenesis of IGM

## Diagnosis

Confirmation of diagnosis of IGM is based upon typical histopathology of chronic lobulocentric granulomatous inflammation without caseation in absence of other benign granulomatous diseases of Breast like Wegner's Granulomatosis, Tuberculosis, Sarcoidosis, Foreign body reaction, Mycotic infection like Histoplasmosis and Mammary duct ectasia including plasma cell mastitis, periductal mastitis and subareolar granuloma and malignancy like inflammatory carcinoma of Breast [1-4,6,8,13]. FNAC leads to cytological dilemma due to similar picture of mixed inflammatory infiltrate in majority of inflammatory granulomatous breast diseases. Lab tests for parameters such as C-reactive Protein, Rheumatoid factor and Antinuclear Antibody are done to rule out autoimmunity [12]. Although not pathognomonic, Several studies highlights following Imaging features of IGM on Ultrasonography (USG), Mammography and Magnetic Resonance Imaging(MRI) [3, 6,10-13] :-

a) USG shows multiple clustered irregular tubular hypoechoic mass with fistulization to skin/axillary lymphadenopathy,a lobulated hypoechoic mass with or without parenchymal irregularities

b) Mammography shows focal asymmetric density or mass with dense parenchymal pattern, no distinct margin and skin thickening, an irregular/Ellipsoid mass, retraction and heterogeneity of breast

parenchyma. Presence of Microcalcification can be confused with Malignancy

c) Magnetic Resonance imaging exhibiting a benign time-signal intensity pattern curve

All these imaging findings in combination with clinical features may give a possible clue towards diagnosis of IGM. Definitive diagnosis of IGM requires histopathological examination of breast lump. Classical Histopathological features reported by various studies to diagnose IGM given in Table 1 [1-6,8].

**Table 1:** Histopathological Features of IGM

- Granuloma Formation
- Lobulocentric Distribution
- Mixed chronic inflammatory infiltrate (predominantly neutrophils, lymphocytes, plasma cells, multinucleate giant cells and epithelioid histiocytes )
- No caseous necrosis
- Micro abscess formation
- Confluence of lobulocentric distribution in severe cases
- Squamous Metaplasia of lobular and ductal epithelium

As Most of the published literature on IGM shows its ethnicity in Mediterranean region and developing countries, Tuberculosis Mastitis (TM) becomes an important differential diagnosis due to high prevalence of Tuberculosis in these countries [2]. In developing countries like India, TM makes 3% of all treatable breast lesion [6] and according to some studies, IGM might reflect under diagnosed TM cases. [2,3,13]. Clinically, IGM presents more similarity with Inflammatory Breast Carcinoma while Pathologically, it resembles more like Tuberculosis [12]. Mantoux test, Past history of Tuberculosis, Chest X-ray and Ziel-Nelson staining for Acid fast bacilli are routinely done to rule out tuberculosis [3,12,13]. In contrast to IGM, TM clinically presents in older patients with previous history of pulmonary tuberculosis or tuberculosis lymphadenitis with bilateral tender masses and axillary lymphadenopathy, persistent abscess and sinuses and on histopathology shows more fibrosis, caseation necrosis and eosinophils [3,13]. In our patient, we kept TM as first differential diagnosis being in endemic zone for Tuberculosis. Other granulomatous diseases like Sarcoidosis were also entertained and patient was thoroughly investigated.

Excluding infectious etiology and malignancy and Correct timely Diagnosis of IGM is important in preventing exacerbating of inflammatory granulomatous mastitis by Corticosteroids, to avoid side effects of Long term use of corticosteroids like Glucose intolerance and Cushingoid features and to prevent radical surgeries, exposure to chemo-radiation and mental agony to the patient [3,4,10,13]. In diagnosed cases of IGM, Various non-surgical conservative expectant treatment in the form of broad spectrum Antibiotics, oral corticosteroids, immunosuppressive therapy like methotrexate, azathioprine, colchicine and surgical treatment modalities like Incision and drainage along with wide local excision have been reported in literature depending on the symptoms and duration of the disease [3,4,6,8]. According to study done by Lei et al, complete resolution of breast lump occurs after taking non-surgical conservative treatment in 50%

patients for 14.5 months (Range 2-24 months) [9]. Other treatment modalities used in the treatment are based on whether IGM is new onset or recurrent. In new onset cases, considering Autoimmune hypothesis, a short course of steroid, oral systemic prednisolone starting with 08.mg/kg/day and tapering over 3- 6 months with clinical improvement has been recommended [5,6,12]. Our patient was started on gradually tapering low dose Oral Steroid Therapy for six months with regular visits in Surgical Out patient department to check for any recurrence.

IGM relapse rate have been reported as high as 5-50% even after surgical excision and after tapering of corticosteroids therapy [4,6]. Recurrent cases require immunosuppressive therapy in combination with Incision and drainage of abscesses. Possibility of TM should be ruled out by Tuberculosis Polymerase Chain reaction before steroid therapy [3]. Breast conservative surgical treatment options in the form of wide local excision are for refractory patients who have developed persistent wound infection and abscess, fistula and draining sinus formation [3,4,6]. In our patient, after 6 months of low dose oral steroid therapy, Her swelling completely subsided gradually without any sinus or fistula formation and after one year post surgery, patient has not reported any relapse.

## Conclusion

IGM, a rare diagnosis of exclusion with favorable prognosis requires multidisciplinary approach to differentiate it from inflammatory breast carcinoma or other granulomatous breast mastitis. Correct timely diagnosis of IGM is important in preventing misuse of Steroids in inflammatory granulomatous mastitis and avoiding long term complication of Steroid treatment. Unnecessary radical surgeries, chemotherapy and mental harassment to the patients can also be reduced by correctly diagnosing IGM in cases clinically radiologically presenting as inflammatory Breast Carcinoma.

## References

1. Kessler E, Wolloch Y. Granulomatous Mastitis: a lesion clinically simulating carcinoma. *Am J Clin Pathol* 1972; 58: 642-646.
2. Altintoprak F, Kivilcim T, Ozkan OV. Aetiology of idiopathic granulomatous mastitis. *World J Clin Cases* 2014; 2(12): 852-858.
3. Bani-Hani KE, Yaghan RJ, Matalka II, Shatnawai NJ. Idiopathic granulomatous mastitis: time to avoid unnecessary mastectomies. *Breast J* 2004; 10: 318-322.
4. Tuli R, O'Hara BJ, Hines J, Rosenberg AL. Idiopathic granulomatous mastitis masquerading as carcinoma of the breast: a case report and review of literature. *Int Semin Surg Oncol* 2007; 4: 21.
5. Going JJ, Anderson TJ, Wilkinson S, Chetty U. Granulomatous lobular mastitis. *J Clin Pathol* 1987; 40: 535-540.
6. Korkt E, Akcay MN, Karadeniz E, Subasi ID, Gursan N. Granulomatous Mastitis: A Ten year experience at a University Hospital. *Eurasian J Med* 2015; 47: 165-73.
7. Patel RA, Strickland P, Sankara IR, Pinkston G, Many W Jr, Rodriguez M. Idiopathic Granulomatous Mastitis: case reports and review of literature. *J Gen Intern Med*. 2010; 25(3): 270-3.
8. Al-Khaffaf B, Knox F, Bundred NJ. Idiopathic granulomatous mastitis: a 25-year experience. *J Am Coll Surg* 2008; 206: 269-273.
9. Lai EC, Chan WC, Ma TK, Tang AP, Poon CS, Leong HT. The role of conservative treatment in idiopathic granulomatous mastitis.



Breast J 2005, 11: 454-456.

10. Binesh F, Kargar S, Zahir ST, Behniafard N, Navabi H et al. Idiopathic granulomatous mastitis, a clinicopathological review of 22 cases. J Clin Exp Pathol, 2014; 4: 157.

11. Lee Jei Hee et al. Radiologic and clinical features of Idiopathic Granulomatous Lobular mastitis mimicking Advanced Breast Cancer. Yonsei Med J 2006; 47: 78-84(1).

12. Omranipur R, Mohammadi S-Farzad, Samimi P. Idiopathic Granulomatous Lobular Mastitis-Report of 43 cases from Iran; Introducing a preliminary clinical practice guideline. Breast Care 2013; 8: 439-443.

13. Seo HRN, Na KY, Yim HE, Kim TH, Kang DK, Oh K et al. Differential diagnosis in idiopathic granulomatous mastitis and tuberculosis mastitis. J Breast Cancer 2012; 15(1): 111-8.

14. Garcia-Rodriguez JA, Pattullo A. Idiopathic granulomatous mastitis: a mimicking disease in a pregnant woman: a case report. BMC Research Notes 2013; 6: 95.

15. Gurleyik G, Aktekin A, Aker F, Karagulle H, Saglamc A. Medical and Surgical treatment of idiopathic granulomatous lobulşar mastitis: A benign inflammatory disease mimicking invasive carcinoma. J Breast Cancer 2012; 15: 119-23.

**Manuscript Information:** Received: November 26, 2018; Accepted: April 13, 2019; Published: April 15, 2019

**Authors Information:** Hemant Sharma<sup>1\*</sup>; Shivani Prashar<sup>2</sup>

<sup>1</sup>Department of Pathology, Government Hospital, Danapur Cantt, Patna, Bihar, India.

<sup>2</sup>Medical Officer, Government Hospital, Danapur Cantt, Patna, Bihar, India.

**Citation:** Sharma H, Prashar S. Idiopathic granulomatous mastitis mimicking inflammatory carcinoma breast: Case report and literature review. Open J Clin Med Case Rep. 2019; 1532.

**Copy right statement:** Content published in the journal follows Creative Commons Attribution License (<http://creativecommons.org/licenses/by/4.0>). © Sharma H 2019

**About the Journal:** Open Journal of Clinical and Medical Case Reports is an international, open access, peer reviewed Journal focusing exclusively on case reports covering all areas of clinical & medical sciences.

Visit the journal website at [www.jclinmedcasereports.com](http://www.jclinmedcasereports.com)

For reprints and other information, contact [info@jclinmedcasereports.com](mailto:info@jclinmedcasereports.com)