

Staphylococcal scalded skin syndrome in an immunocompetent healthy adult patient: A rare presentation

Ghanshyam Verma*; GR Tegta; Renu Rattan; Reena Sharma; Prajul Mehta; Nancy Lalnunpuui

*Ghanshyam Verma

Associate Professor, Department of Dermatology, Indira Gandhi Medical College, Shimla, Himachal Pradesh, India.

Email: drshyamverma77@gmail.com

Abstract

Staphylococcal scalded skin syndrome (SSSS) is a disorder that is usually seen in infants and children and rarely, in adults. SSSS usually presents with a prodrome of sore throat or conjunctivitis. Extremely tender flaccid bullae develop within 48 hours and rupture easily to reveal a moist erythematous base, which gives rise to the scalded appearance. The severity ranges from a localized form to a severe exfoliation affecting almost the entire body. SSSS is caused by *Staphylococcus aureus*, which leads to separation at the granular layer level in the epidermis, by the release of circulating exotoxins A and B which cleave desmoglein-1. SSSS in adults is a rare disorder which occurs in predisposed individuals, but not all adults have an underlying illness. Mortality is less than 10% in children, but is between 40% and 63% in adults, due to co-morbidities. We report a case of Staphylococcal scalded skin syndrome, presenting unilaterally in an immunocompetent adult without any comorbidities, that has been rarely reported in the literature.

Keywords

staphylococcal scalded skin syndrome; adult; exfoliative toxins; desmoglein-1

Abbreviations

SSSS: Staphylococcal scalded skin syndrome; ETB: Exotoxin B; ETA: Exotoxin A

Introduction

The Staphylococcal Scalded Skin Syndrome, a superficial blistering disorder, is caused by exotoxins, exotoxin A(ETA) and exotoxin B(ETB) released by *Staphylococcus aureus*, which act as atypical serine proteases and desmoglein-1 being the substrate for them, leading to break down in the granular layer of the epidermis. The condition was first described by a German physician, Von Rittershain, in 1878 [1]. The disease is seen most commonly in infants and children, being rare in adults. This has been attributed to the ability of adults to metabolize and excrete exotoxins rapidly or to acquired immunity. SSSS in adults was

first described in 1972 by Levine and Norden [2]. The annual incidence of SSSS among US adults was 0.98 (range 0.94-1.02) cases/million. There was a report of increase in overall incidence (by 47.1%) of SSSS, among infants increase by (81.0%) and maximum in 1-17 years age group increase by (83.8%), while they reported decrease by 15.4% among adult patients, with associated substantial morbidity and mortality [3]. The incidence was 0.39/ 100,000 persons in the UK [4]. In adults, mortality rates can be as high as 60% due to serious underlying illnesses. However, in children mortality is generally lower, around 4% [5]. Fewer than 20 instances of adult SSSS have been reported in the literature; none of the isolates produced ETB [6, 7] as this exotoxin ETB was associated with adult onset SSSS in healthy cases. The lesions are superficial and heal rapidly without scarring with appropriate therapy. We report the occurrence of SSSS in a previously healthy adult which constitutes a rare presentation.

Case Presentation

A 48-year-old male manual worker presented to our dermatology department with fluid-filled painful lesions over his right arm and adjoining upper trunk for one day. He started developing multiple fluid-filled lesions over right forearm followed by right arm, right side of trunk in a day which gradually ruptured to form a painful raw area. He denied fever, sore throat, chest pain, cough, shortness of breath or any urinary complaint. There was no suggestion of any injury or prior redness at the site of the lesions. There was no prior history of drug intake or application of any irritant or any herbal medicine over the affected sites.

No complaint of photosensitivity, joint pain, oral, genital, perianal lesions or any systemic complaints. On physical examination he was afebrile and hemodynamically stable. We observed salmon red colored erosions with rolled superficial skin layers over the right arm, axilla, adjoining upper trunk and left proximal upper limb posteriorly with perilesional erythema and pustules (Figure 1,2,3). The size of lesions varied from 2 - 20 cm in diameter approximately. The lesions were tender with a positive Nikolsky's sign. There was no evidence of oral and genital ulceration. Patient was clinically diagnosed as a case of staphylococcal scalded skin syndrome and was started on empirical therapy with administration of ceftriaxone 1gm intravenously twice a day with supportive care such as daily wound dressing and topical antibiotics. Routine investigations were all within normal limits except a raised ESR, CRP (131.7) and ASO (>200), proteinuria of 2+ and 7-10 WBC/hpf on routine urine microscopy. Ultrasonography of abdomen and pelvis was normal. Serology for HIV antibodies was non-reactive. The blood and urine culture were sterile. However, throat swab culture revealed growth of *staphylococcus aureus* and bacterial culture from lesion revealed *Klebsiella pneumoniae* species.

Skin biopsy revealed a sub corneal split at the level of the granular layer of epidermis (figure 5) with pustules with neutrophils and acantholytic epithelial squamous cell. Papillary dermis was edematous with a perivascular infiltrate of neutrophils, macrophages and lymphocytes in a band-like pattern along the vessels. Infiltrate was also extending to lower or reticular dermis. Histopathologic findings were confirmatory of SSSS. After a period of 10 days of hospitalization he was discharged without any complications.

Figures

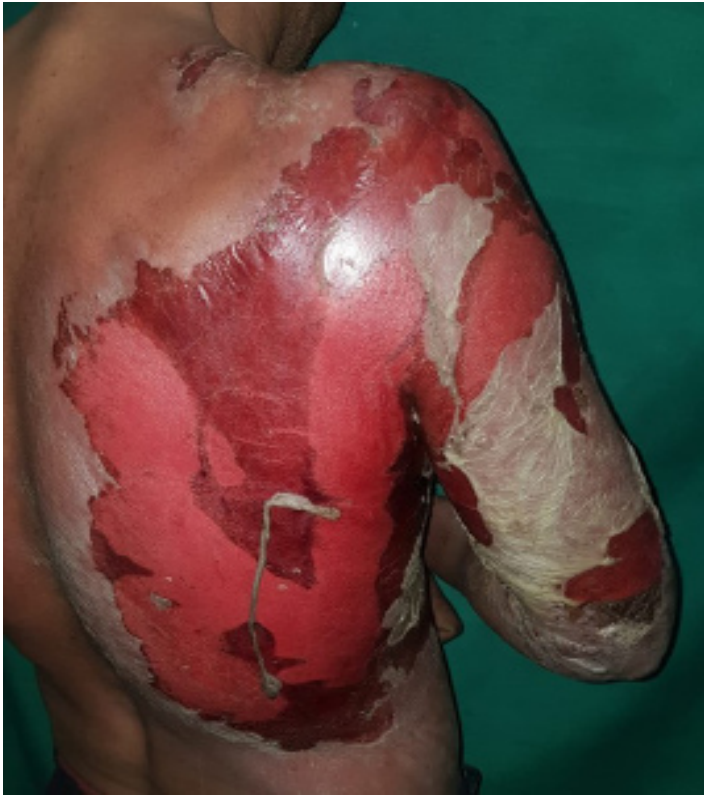

Figure 1: Salmon red colored erosions with peeling of superficial skin layer over the right arm and adjoining posterolateral trunk.

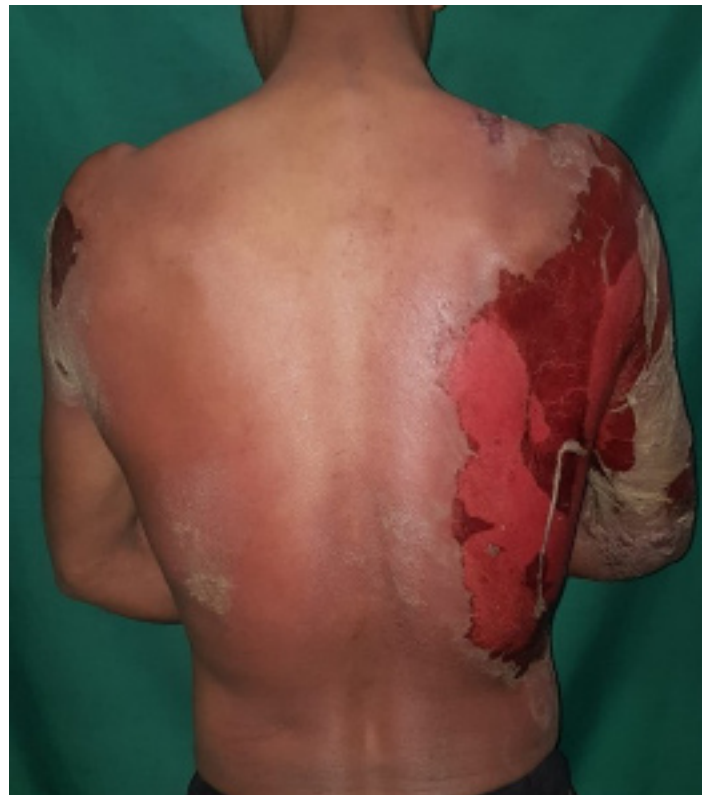

Figure 2: Salmon red colored erosions with peeling and desquamation of the superficial layers of skin over back (right side) and a smaller patch over left shoulder with relative sparing of central part of back.

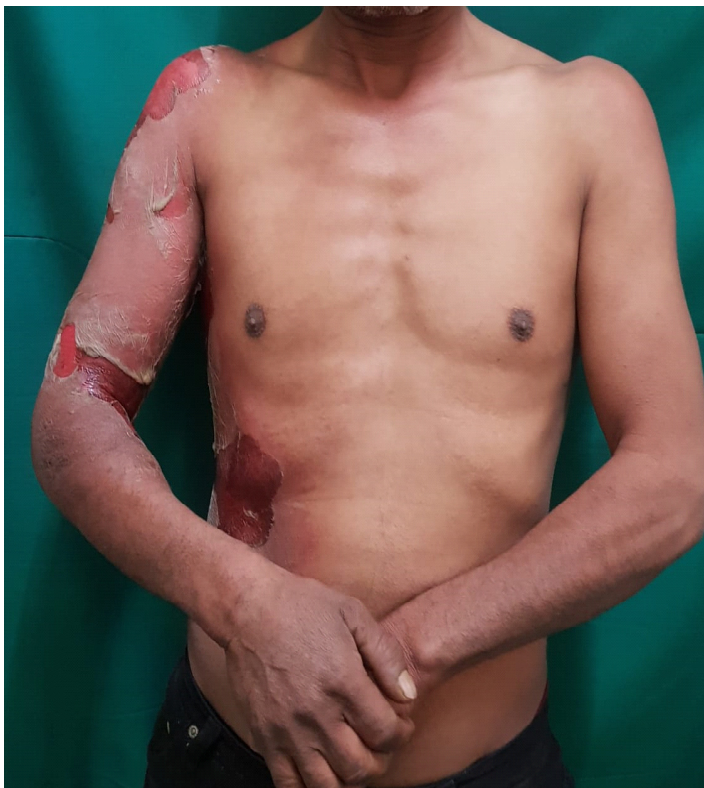

Figure 3: Anterior aspect of lesion over right forearm and arm and lateral aspect of trunk.

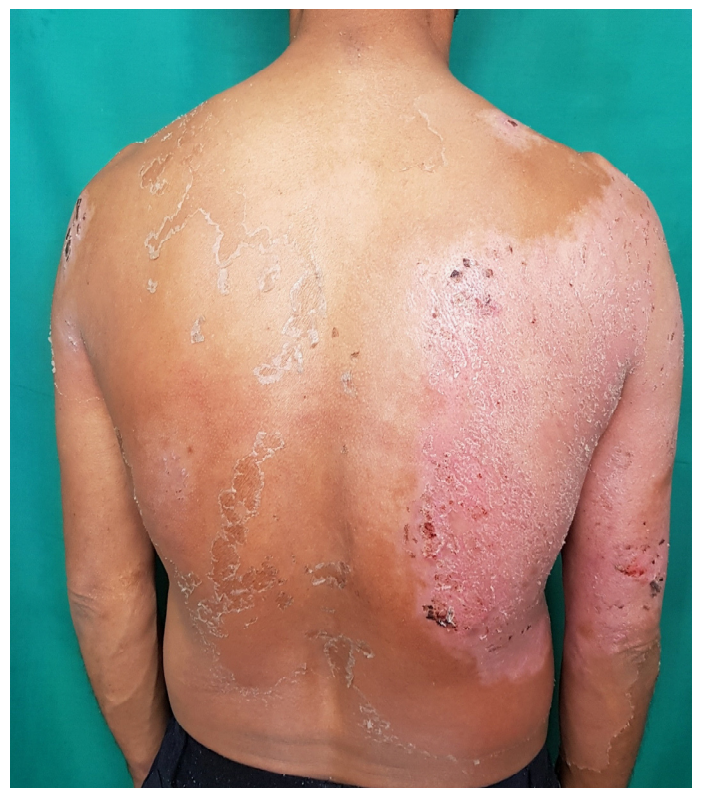

Figure 4: Lesions healing with rapid re-epithelialization after 10 days of antibiotic therapy.

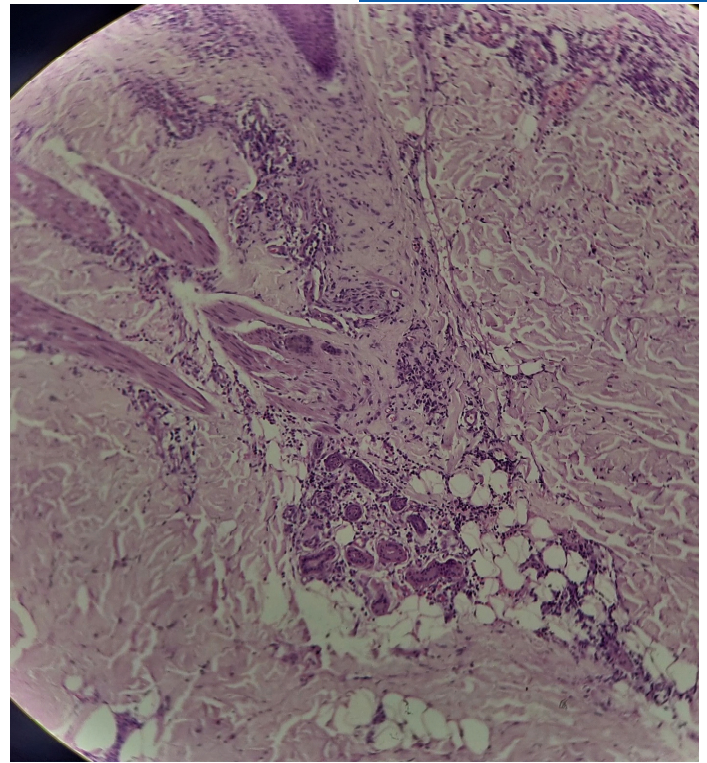
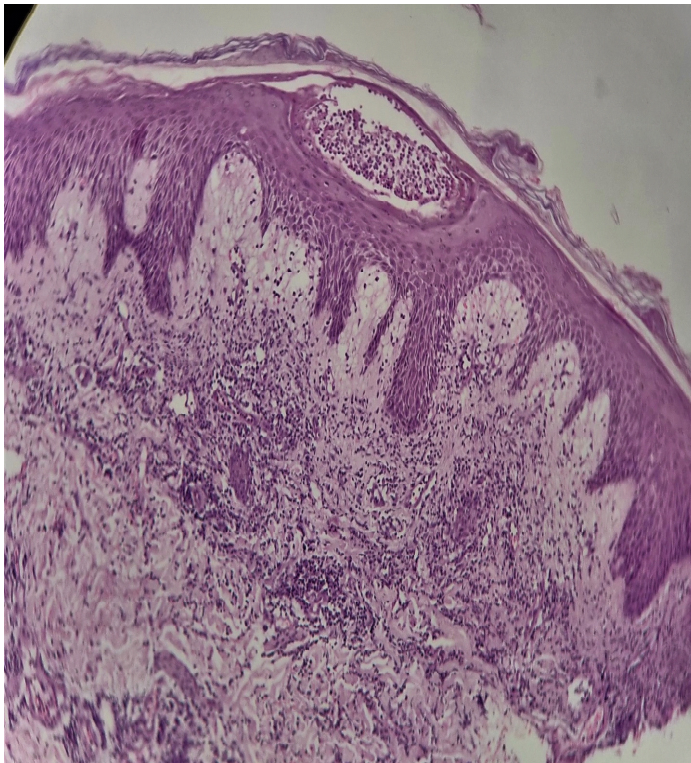


Figure 5: (H&E stained 10X) photomicrograph revealed, sub-corneal split at the level of granular layer of epidermis with pustules with neutrophils and acantholytic squamous epithelium. **Figure 6:** (H&E stained 100X) photomicrograph revealed, edematous papillary dermis with perivascular infiltrate of neutrophils, macrophages and lymphocytes in a band like pattern along the vessels extending down to lower dermis.

Discussion

Staphylococcal scalded skin syndrome is also called as Ritter von Ritterschein disease, Ritter disease, Lyell disease and staphylococcal necrolysis of epidermis [8]. It is a potentially life-threatening disorder caused by *staphylococcus aureus* infection. Now it has been shown that 5% of *staphylococcus aureus* are capable of producing exotoxins, not only phage II groups [9]. Exotoxin A (ETA) and B (ETB) are serine proteases which disseminate haematogenously and binds to the filaggrin in keratohyalin granules and because filaggrins act as intracellular anchors of desmosomes, it digests desmoglein 1 (Dsg1), leading to separation at the level of stratum granulosum, resulting in widespread superficial bullae formation and rapid denudation. ETA also activates murine macrophages to release tumor necrosis factor, interleukin-6 and nitric oxide [9,10]. It is most common in children less than 5 years of age affecting male and female equally whereas in adults, it is more common in males [11]. *S. aureus* can enter the skin through a break in the skin barriers such as grazes, atopic dermatitis or chickenpox and produces the toxin locally, whereas in generalized form, toxins are usually produced at distant sites.

Virtually all adults with SSSS are immunocompromised, with chronic renal disease, HIV infection, graft versus-host disease, malignant neoplasms, chemotherapy, intravenous drug abuse or diabetes mellitus. A suppressed immune system results in an inability to produce antibodies. Patients undergoing hemodialysis or IV drug abuse are at risk due to infection by *S. aureus* through vascular access ports. Renal failure patients have inability to excrete ET, and have immunological deficits. Currently, 46.8% of adults

over 70 years of age have chronic kidney disease [12]. In cases of adults without immunosuppression, it is likely that they contracted strains of *S. aureus* with the *etb* gene which encodes virulent exotoxin ETB [11].

Only 36% of SSSS cases were in adults [13] presenting with a prodrome of malaise and fever, followed by abrupt, faint, erythematous, tender patches. Within 24-48 hours fluid-filled blisters appear which rupture easily, leaving an area that looks like a burn [14], involving axillae, groin and neck, leaving swaths of moist, red surface that appears scalded with a positive Nikolsky's sign. But the mucosal surfaces are usually not involved since desmoglein-1 is only found in epidermis. The denuded skin is a source for fluid loss, dehydration, temperature dysregulation and secondary infection. Within 24 hours, the areas dry up with a thin, shiny crust and fissures. The lesion may extend for 24–48 hours after onset until circulating exotoxins has been neutralized by antibodies or excreted via the kidneys. Within 14 days the skin heals without scarring, because of the superficial location of epidermal insult at which the rupture occurs .

Blood cultures are usually negative in children whereas in the majority of adults, *staphylococcus aureus* grows. Cultures should be performed from blood, wounds, ocular exudates and nasopharynx. In adults, primary infection such as pneumonia, osteomyelitis or septic arthritis may be the foci. In children it is usually a mild upper respiratory tract infection the focus of *staphylococcus aureus* infection. A skin biopsy specimen shows superficial intraepidermal cleavage under the stratum corneum. Both TEN and SSSS lack inflammation, but SSSS does not have the necrotic keratinocytes characteristic of TEN. Histology of SSSS is also consistent with pemphigus foliaceus and bullous impetigo [11]. To detect the toxins, polymerase chain reaction, enzyme-linked immunosorbent assays and radio-immuno assays have been developed [14].

Initiation of antibiotics as early as possible with supportive measures such as fluids and antipyretics. Penicillinase-resistant penicillins are recommended such as flucloxacillin. For penicillin-allergic individuals, clarithromycin or cefuroxime. For methicillin-resistant *S. aureus* (MRSA), switch to vancomycin [15]. Children may receive fresh frozen plasma. If not improved, a 5-day course of intravenous immunoglobulin [11]. In the future, analogs of desmoglein-1 could be used to neutralize the toxins. [9].

In the present case interesting points were that he was immunocompetent without any comorbid condition, *staphylococcus aureus* was isolated from the throat with asymptomatic infection. He developed secondary cutaneous infection at lesional site with *klebsiella pneumoniae*. The extent of lesions of SSSS was limited to one region of the body and relatively unilateral. Although we could not establish the type of exotoxin involved in causation of his SSSS, it may be ETB with which this condition has been described in healthy adult individuals [16].

Conclusion

SSSS is a rare occurrence in adults it is even less common in healthy immunocompetent adult patients. Patient should be managed with appropriate therapy as early as possible to avoid complications. Adults should be worked up thoroughly to rule out any other underlying comorbid condition.

References

1. Von Rittershain G. Die exfoliative Dermatitis jungerer Sauglinge. Zent-Ztg Kinderheilkunde. 1878; 2: 3–23.
2. Levine G, and C W Norden. Staphylococcal scalded skin syndrome. Clinical features, pathogenesis, and recent microbiological and biochemical developments. Arch Dermatol. 1972; 113: 207-219.
3. Staiman, Alanna et al. Epidemiology of staphylococcal scalded skin syndrome in US adults. J Am Acad Dermatol. 2018; 79: 774 – 776.
4. Arnold JD, Shelby NH, Kirko Mrian Y. Epidemiology of staphylococcal scalded skin syndrome in the United States: A cross-sectional study 2010-2014. J Am Acad Dermatol. 2018; 78: 404-406.
5. Patel GK, Finlay AY. Staphylococcal scalded skin syndrome: diagnosis and management. Am J Clin Dermatol. 2003; 4: 165–75.
6. Neefe, LI, Tuazon CU, Cardella TA, Sheagren JN. Staphylococcal scalded skin syndrome in adults: case report and review of the literature. Am. J. Med. Sci. 1979; 277: 99-110.
7. Richard, M., and A. Mathieu-Serra. Staphylococcal syndrome in a homosexual adult. J. Am. Acad. Dermatol. 1986; 15: 385-389.
8. Mishra AK, Yadav P, Mishra A. A Systemic Review on Staphylococcal Scalded Skin Syndrome (SSSS): A Rare and Critical Disease of Neonates. Open Microbiol J. 2016; 10: 150-159.
9. Ladhani S. Recent development in Staphylococcal scalded skin syndrome. Clin microbiol infection. 2001; 7: 301-307.
10. Ladhani S, Evan R. Staphylococcal scalded skin syndrome. Arch Dis Child. 1998; 78: 85-88.
11. Handler MZ, Schwartz RA. Staphylococcal scalded skin syndrome: diagnosis and management in children and adults. 2014; 28: 1418-23.
12. Stevens LA, Viswanathan G, Weiner DE. CKD and ESRD in the elderly: current prevalence, future projections, and clinical significance. Adv Chronic Kidney Dis. 2010; 17: 293–301.
13. Mockenhaupt M, Idzko M, Grosber M, Schopf E, Norgauer J. Epidemiology of staphylococcal scalded skin syndrome in Germany. J Invest Dermatol. 2005; 124: 700–703.
14. Sethuraman KM, Avabratha KS, Vanghese AD, Rai BS. Staphylococcal scalded skin syndrome: A dermatological emergency in pediatrician's hand. Med J DY Patil Univ. 2014; 7: 189-191.
15. Blyth M, Estela C, Young AE. Severe staphylococcal scalded skin syndrome in children. Burns 2008; 34: 98-103.
16. Opal SM, Johnson-Winegar AD, Cross AS. Staphylococcal scalded skin syndrome in two immunocompetent adults caused by exfoliatin B-producing Staphylococcus aureus. J Clin Microbiol. 1988; 26: 1283-86.

Manuscript Information: Received: January 16, 2019; Accepted: March 27, 2019; Published: March 29, 2019

Authors Information: Ghanshyam Verma¹, GR Tegta², Renu Rattan³, Reena Sharma⁴, Prajul Mehta⁵, Nancy Lalnunpui⁶

¹Associate Professor, Department of Dermatology, Indira Gandhi Medical College, Shimla, Himachal Pradesh, India.

²Professor and Head, Department of Dermatology, Indira Gandhi Medical College, Shimla, Himachal Pradesh, India.

³Assistant Professor, Department of Dermatology, Indira Gandhi Medical College, Shimla, Himachal Pradesh, India.

⁴Senior Resident, Department of Dermatology, Indira Gandhi Medical College, Shimla, Himachal Pradesh, India.

⁵Junior resident Department of Dermatology Indira Gandhi Medical College, Shimla, Himachal Pradesh, India.

⁶Junior resident Department of Dermatology, Indira Gandhi Medical College, Shimla, Himachal Pradesh, India.

Citation: Verma G, Tegta GR, Rattan R, Sharma R, Mehta P, Lalnunpui N. Staphylococcal scalded skin syndrome in an immunocompetent healthy adult patient: A rare presentation. Open J Clin Med Case Rep. 2019; 1527.

Copy right statement: Content published in the journal follows Creative Commons Attribution License (<http://creativecommons.org/licenses/by/4.0>). © Verma G 2019

About the Journal: Open Journal of Clinical and Medical Case Reports is an international, open access, peer reviewed Journal focusing exclusively on case reports covering all areas of clinical & medical sciences.

Visit the journal website at www.jclinmedcasereports.com

For reprints and other information, contact info@jclinmedcasereports.com