

Benign, recurrent, alternating Tolosa Hunt Syndrome –A case report

Murali Krishna Menon; Shani Basheer; Shirley Joan Fernandez; Muhammed Jasim Abdul Jalal*

***Muhammed Jasim Abdul Jalal, MBBS, DNB**

Department of Internal Medicine and Rheumatology, VPS Lakeshore Hospital, Kochi, Kerala, India
Phone: 91 954 4020621; Email: jasimabduljalal@yahoo.com

Abstract

Tolosa Hunt Syndrome (THS) is an acute ophthalmoplegia. It may or may not involve optic nerve and ophthalmic division of trigeminal nerve. THS responds promptly to steroid treatment. Recurrence of THS is common, that too on the same side. But involvement of the alternating side is quite rare. Here, we describe an unusual case of recurrent alternating THS wherein the patient had painful ophthalmoplegia in alternate eyes after an interval of one year.

Keywords

Tolosa Hunt Syndrome; optic nerve; ophthalmoplegia

Introduction

Tolosa-Hunt syndrome (THS) is a neurological entity, which constitutes acute painful ophthalmoplegia with or without involvement of optic nerve and ophthalmic division of trigeminal nerve. The neurological localization in THS may be in the cavernous sinus or the superior orbital fissure [1]. Recurrence of THS is common, that too on the same side. Involvement of the contralateral cavernous sinus/superior orbital fissure, known as alternating THS, is very rare. THS responds promptly to steroid therapy. We report an unusual case of recurrent alternating THS wherein the patient had painful ophthalmoplegia in opposite eyes after an interval of one year.

Case Report

A 54-year-old male, with no known co-morbidities, presented with left sided retro orbital pain of 1 week duration. The pain was continuous, non-throbbing, and moderately severe in intensity and not associated with nausea, vomiting or fever. He denied discharge from eyes, diurnal or postural variations. He gradually developed drooping of left eye lid with associated binocular diplopia. There was no history of any trauma, visual loss, and change in voice or dysphagia. The right eye was asymptomatic.

Examination revealed dilated, sluggishly reactive left pupil with restricted superior, inferior and medial ocular movements suggestive of left complete third nerve palsy. Right eye was normal. Bilateral fundus examination did not show any exudates, hemorrhages or evidence of papilloedema. Other cranial nerves and neurological examination was unremarkable.

Routine blood counts and blood biochemical work up were normal. Erythrocyte sedimentation

(ESR), C - reactive protein (CRP) and Angiotensin converting enzyme (ACE) were within normal limits. Rheumatoid factor, Perinuclear Anti-Neutrophil Cytoplasmic Antibodies (p-ANCA), Cytoplasmic Anti-Neutrophil Cytoplasmic antibodies (c-ANCA) and Antiphospholipid antibodies (APLA) were all negative. Cerebrospinal fluid (CSF) study showed 5 WBCs per mm [3]. CSF protein was 60mg/dl. CSF sugar was 80mg/dl. Visual evoked responses suggested delay of latency and decreased amplitude on the left side favoring left anterior pathway dysfunction but had normal parameters on the right side (Figure 1 and Figure 2). Magnetic resonance imaging (MRI) brain and orbit were within normal limits (Figure 3 and Figure 4).

Patient was initially pulsed with 500mg of methyl prednisolone as intravenous infusion for 3 days. Later on, he was commenced on oral methyl prednisolone in tapering dose. Pain resolved in 2 days and the eye movements improved.

One year ago, he was admitted with similar complaints in the right eye. Examination revealed right oculomotor palsy with normal fundus. Left eye was normal. Similar to the present instance, all his work up were within normal limits and had complete resolution of his symptoms with high dose steroids in 2 weeks.

Discussion

In 1954, Tolosa E first described Tolosa-Hunt syndrome (THS) [2]. It occur secondary to idiopathic granulomatous inflammation of the cavernous sinus or superior orbital fissure [3]. In 1962, Hunt et al reported six cases of painful ophthalmoplegia; that rapidly improved with the use of steroids [4].

Primary THS is basically a diagnosis of exclusion. Diagnostic work-up includes routine blood work, inflammatory markers, fasting glucose, CSF study, vasculitic profile screening [ANA, anti-dsDNA, c-ANCA, p-ANCA etc.], MRI, conventional angiography or MRA; and in some cases biopsy. THS rapidly improves with high dose steroids (1 mg/kg/day) tapered slowly over 2 to 3 months.

In 1988, Lance and Olesen first described the criteria for THS in the International Headache Society (IHS) and later modified it in the revised IHS headache classification of 2004 [5,6]. In 2006, La Mantia et al classified THS based on the neuroimaging findings [7] as

- 1) benign (when no abnormal neuroimaging could be found),
- 2) inflammatory (when inflammatory findings were shown on MRI or biopsy) and
- 3) Symptomatic (when neuroimaging revealed specific lesion).

On review of published literature, only five articles mentioned about MRI documented alternating THS out of the 233 articles of THS from 1966 to 2017. In 1975, Lapresle reported a case of alternating THS diagnosed with carotid and vertebral angiography, orbital phlebography and air encephalography [8]. In 1989, Ohshima described a case of alternating THS diagnosed with cavernous sinus and orbital venography in a diabetic patient [9]. In 2010, Guedes et al reported MRI documented case report of alternating THS [10]. Further in 2010, Navi and Safdieh reported MRI documented recurrent alternating THS in a 24-year-old female [11].

In 2013, Lekhra OP et al reported another MRI documented recurrent alternating THS in a 25-year-old woman [12]. To the best of our knowledge there is no other MRI documented case of alternating THS since then.

As per Le Mantia et al classification of THS, our patient had a benign THS since MRI and CSF was normal in both the occasions. Recurrence of THS on the ipsilateral side is well described. Involvement of the contralateral side, known as alternating THS is very rare. In our case, both eyes were involved at an interval of one year. This was further proved by clinical examination. As the patient improved completely with steroids on both the occasions, we assume it to be a case of recurrent alternating THS.

Figures

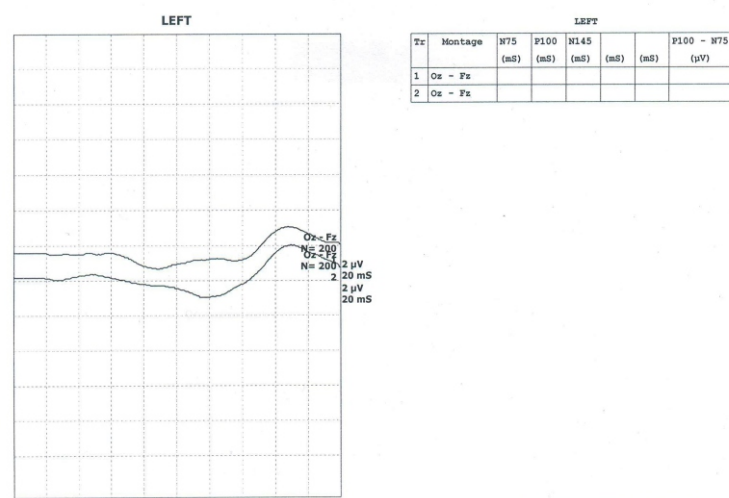


Figure 1: Visual evoked responses showing delay of latency and decreased amplitude on the left side favoring left anterior pathway dysfunction.

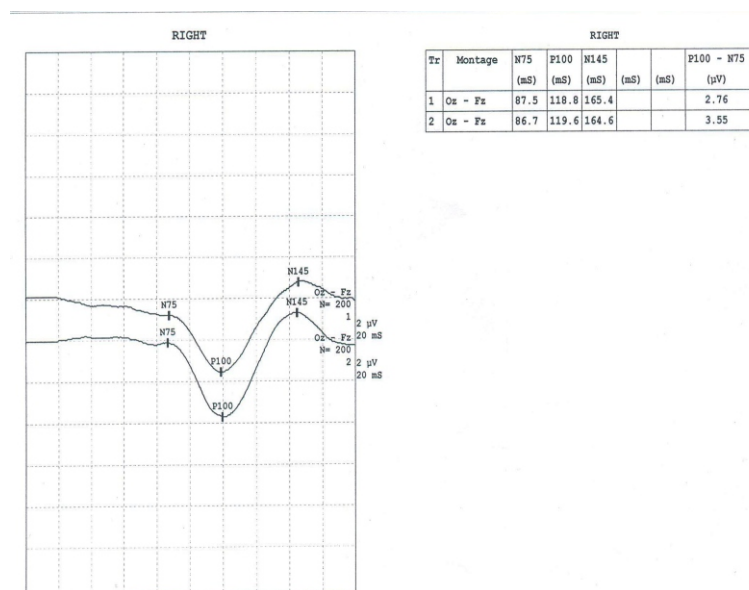


Figure 2: Visual evoked responses showing normal latency and amplitude on the right side favoring normal right anterior pathway.

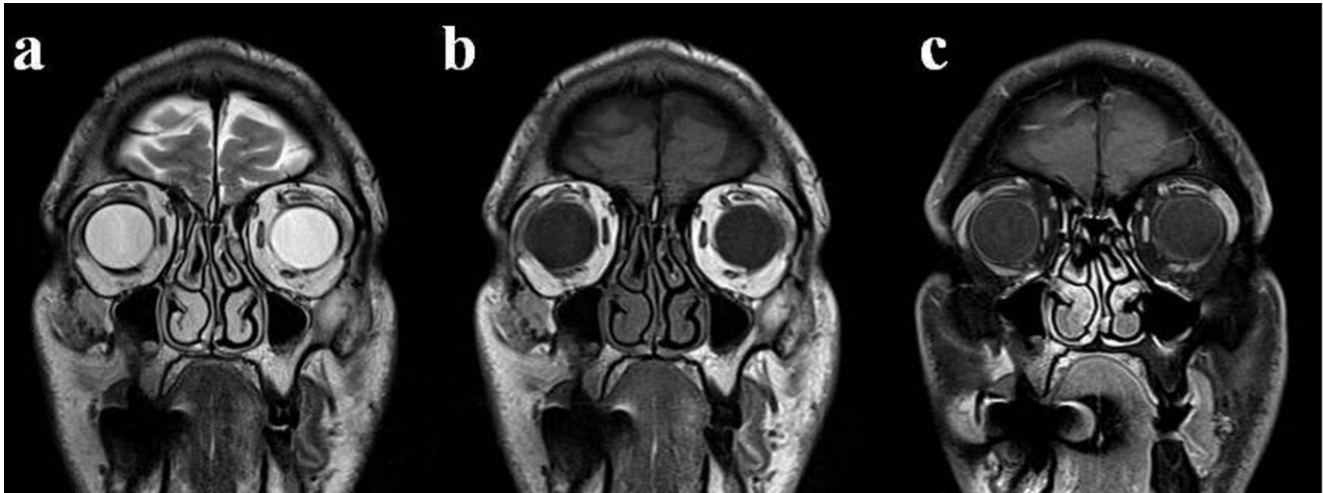


Figure 3: MRI orbit showing normal globe, optic nerve and extra ocular muscles.

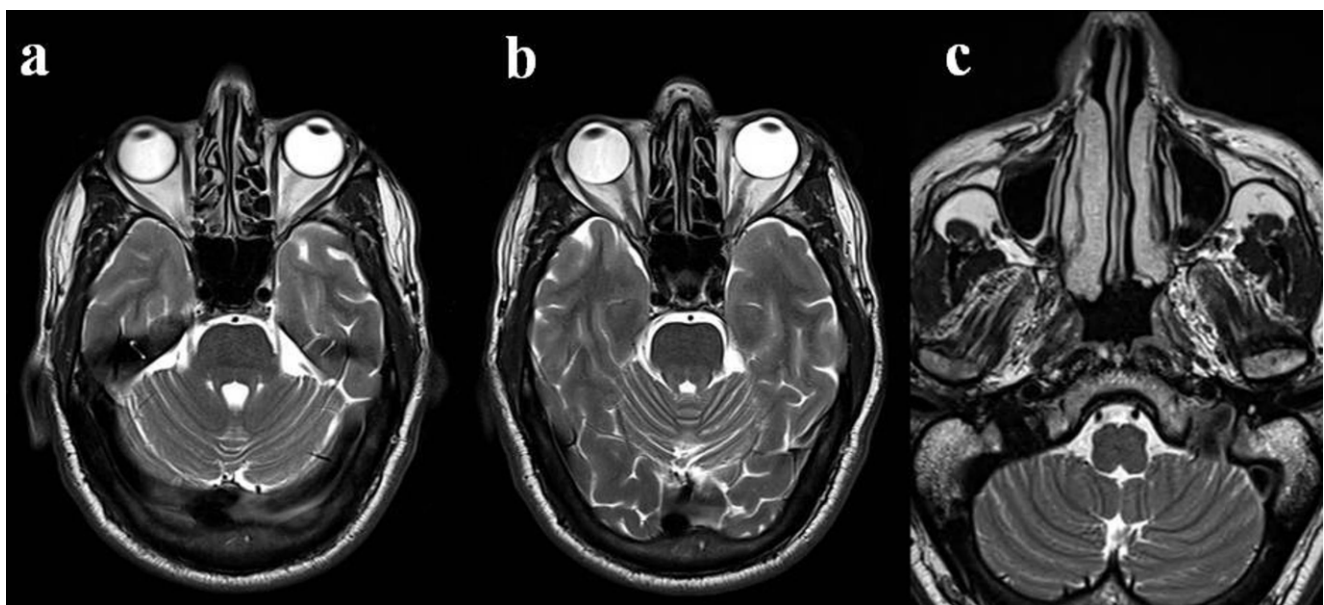


Figure 4: MRI brain showing normal brain parenchyma with normal grey white matter differentiation. no acute infarct, bleed, mass lesion or extra axial collection.

References

1. Gladstone JP. An Approach to the Patient with Painful Ophthalmoplegia, with a Focus on Tolosa-Hunt Syndrome. *Curr Pain Headache Rep.* 2007 Aug; 11(4):317-25.
2. Tolosa E. Periarteritic lesions of the carotid siphon with the clinical features of a carotid infraclinoidal aneurysm. *Journal of Neurology, Neurosurgery & Psychiatry.* 1954 Nov 1; 17(4):300-2.
3. Goadsby PJ, Lance JW. Clinicopathological correlation in a case of painful ophthalmoplegia: Tolosa-Hunt syndrome. *J Neurol Neurosurg Psychiatry.* 1989; 2:1290-1293.
4. Hunt WE, Meagher JN, LeFever HE, Zeman W. Painful ophthalmoplegia. Its relation to indolent inflammation of the cavernous sinus. *Neurology.* 1961 Jan; 11:56-62.
5. Lance JW, Olesen J. Classification and diagnostic criteria for headache disorders, cranial neuralgias and facial pain. *Headache Classification Committee of the International Headache Society. Cephalalgia.* 1988; 8 Suppl 7:1-96.
6. Lance JW, Olesen J. The International Classification of Headache Disorders ICHD-II. *Cephalalgia.* 2004; 24:131.

7. La Mantia L, Curone M, Rapoport AM, Bussone G: Tolosa-Hunt syndrome: critical literature review based on IHS 2004 criteria. *Cephalalgia*. 2006 Jul; 26(7):772-81.
8. Lapresle J, Said G. Painful, alternating and recurrent ophthalmoplegia. Contribution to the study of Tolosa-Hunt syndrome. *Rev Neurol (Paris)*. 1975 Aug; 131(8):583-8.
9. Ohyama M, Tezuka H, Michikawa K, Fukuchi T, Terashi A: *Rinsho shinkeigaku = clinical neurology* 29:3 1989 Mar pg 315-7.
10. BVS Guedes, AJ da Rocha, HB Zuppani, CJ da Silva, WL Sanvito. A case review of the MRI features in alternating Tolosa-Hunt syndrome. *Cephalalgia*. 2010; 30(9):1133-612.
11. Babak B Navi, Joseph E Safdieh. Recurrent, alternating Tolosa-Hunt Syndrome. *Neurologist*. 2010 Jan; 16(1):54-5.
12. Lekhra OP, Patel K, Maheshwari A, Rathore Y. Alternating, Recurrent Tolosa Hunt Syndrome –A Rare Case Report. *IOSR Journal of Dental and Medical Sciences*. 2013 Jan-Feb; 4(5):1-4.

Manuscript Information: Received: August 22, 2017; Accepted: November 28, 2017; Published: November 30, 2017

Authors Information: Murali Krishna Menon¹; Shani Basheer²; Shirley Joan Fernandez¹; Muhammed Jasim Abdul Jalal^{3*}

¹Department of Neurology, VPS Lakeshore Hospital, Kochi, Kerala, India.

²Department of Family Medicine, VPS Lakeshore Hospital, Kochi, Kerala, India.

³Department of Internal Medicine and Rheumatology, VPS Lakeshore Hospital, Kochi, Kerala, India

Citation: Menon MK, Basheer S, Fernandez SJ, Abdul Jalal MJ. Benign, recurrent, alternating Tolosa Hunt Syndrome –A case report. *Open J Clin Med Case Rep*. 2017; 1348.

Copy right statement: Content published in the journal follows Creative Commons Attribution License (<http://creativecommons.org/licenses/by/4.0>). © Abdul Jalal MJ 2017

Journal: Open Journal of Clinical and Medical Case Reports is an international, open access, peer reviewed Journal focusing exclusively on case reports covering all areas of clinical & medical sciences.

Visit the journal website at www.jclinmedcasereports.com

For reprints and other information, contact editorial office at info@jclinmedcasereports.com