

Hemophagocytic syndrome EBV-related associated with leukocytoclastic vasculitis in a type-2 refractory celiac patient

Mario Cottone*; Chiara Sapienza; Chiara Di Mitri; Aroldo Rizzo

***Mario Cottone**

Department of Internal Medicine, University of Palermo, Italy

Phone: 39 338 5358045; Fax: 39 09 16885111; Email: cottonedickens@gmail.com

Abstract

Hemophagocytic lymphohistiocytosis (HLH) is a frequently fatal and likely underdiagnosed disease involving a final common pathway of hyperinflammation, which can result in end-organ damage and death. Although an early diagnosis is crucial to decrease mortality, the definitive diagnosis is often very difficult because of the lack of currently accepted diagnostic criteria and the absence of confirmatory gold standards as well. HLH needs to be differentiated from other conditions like sepsis, SIRS, MODS and macrophage activation syndrome which can mimic HLH. A 44 years-old woman with refractory celiac disease and treated with immunosuppressive therapy who shows the following symptoms: diarrhea, weight loss, fever and erytematous skin lesions. All of culture tests were negatives but was identified Epstein Barr Virus (EBV) in her blood. Persistent fever, blood pancytopenia and increased values of ferritin, triglycerides and liver function indices prompted us to consider HLH as final diagnosis; actually bone marrow biopsy has confirmed this.

This case seems to be a complex one of Hemophagocytic syndrome EBV-related associated with leukocytoclastic vasculitis. Epstein-Barr virus reactivation, due to immunosuppression Cladribine associated, may have promoted a systemic and uncontrolled inflammatory reaction in a celiac-resistant patient. According to this scenario, leukocytoclastic vasculitis found in skin lesions, can be considered a manifestation of this catastrophic chain of events HLH-EBV associated.

Keywords

hemophagocytic lymphohistiocytosis; refractory celiac disease; ebstein barr virus; cutaneous leukocytoclastic vasculitis; immunocompromised patient

Keywords

HLH: Hemophagocytic lymphohistiocytosis; EBV: Epstein Barr Virus

Introduction

Hemophagocytic lymphohistiocytosis (HLH) is a frequently fatal and likely underdiagnosed disease involving a final common pathway of hyperinflammation, which can result in end-organ damage and death. HLH has been traditionally divided into a primary form, which typically manifests in children with documented genetic abnormalities of the cytotoxic function of NK cells and T cells, and a secondary form that tends to occur in adulthood in associated condition settings such as: infection and malignancy,

without an identifiable genetic abnormality [1].

Infections are common triggers in both genetic and acquired HLH and viral infections of the herpes virus family are frequently reported.

Case Report

A 44 years-old woman with refractory celiac disease since 2010 (type 2 diagnosis upon clonal analysis of T cell receptors) (Figure 1) was treated with azathioprine for 5 years without benefits.

In October 2015, an endoscopic/histologic evaluation was performed because of appearance of a diarrhea's appearance and loss of weight as well. The diagnosis of R2 celiac disease was confirmed (figure 1). For this reason a first cycle of Cladribine was performed in hematology unit. After 15 days of treatment, she was admitted at the internal medicine department of our hospital because of persistence of diarrhea, weight loss and erythematous skin lesions.

At first, the patient looked like undernourished, the vital signs were normal and she seemed to be worried and very anxious. Presence of erythematous cutaneous lesions on the abdomen and thorax were observed (Figure 2).

Initial laboratory evaluation of the serum was as follows: glucose 90 mg/dL, creatinine 1.0 mg/dL, total bilirubin 1,00 mg/dL, platelet count 570 K/ml, hemoglobin 11.7 g/dL, mean corpuscular volume 80 fL, red cell distribution width 16.7%, leucocytes 7900, and lactate dehydrogenase 538 U/L, normal transaminases. Coagulation studies were normal and ANA, ANCA were negative.

A chest radiograph had not revealed abnormalities and an electrocardiogram was normal.

Moreover a biopsy of the skin lesions was performed. Ultrasound examination of the abdomen showed hepatosplenomegaly, abdominal lymphadenopathy and a thrombus of 5 cm in the abdominal aorta. For this reason genetic profile for thrombophilia was searched. Homozygosis for PAI and heterozygosity for prothrombin mutation (G20210A) were found, LAC and antiphospholipid antibodies were negative.

When CT angiography confirmed thrombosis of the infrarenal aorta the patient begun antiplatelet and anticoagulant therapy. During the 8th day of this therapy, some episodes of melena occurred, so she underwent to a esophageal-gastrointestinal endoscopy and three duodenal ulcers were found. The drop of Hb from 11.6 gm/ dl to 8.05 gm/dl justified blood transfusions.

After 5 days from admission there was the appearance of long lasting fever and jaundice. AST/ALT increased to 299/163 and bilirubin to 7 mgr/dl and there was a reduction of all blood cells: Hemoglobin 9,3 gr/dl, platelets 107 K/mL. Blood and urine coltures were both negative so viral causes were researched.

Because of an EBV DNA Virus detection (> 6000 copies), acyclovir treatment has begun.

Meanwhile an abdominal ultrasound was repeated and a total disappearance of the aortic thrombus was observed. After ten days, fever persisted and an increase of ferritin values (> 7000ng/ml) and of triglycerides (389 mg/dl) were found. Because of a macrophage activation syndrome(MAS) suspicion a bone marrow biopsy was performed. It showed eritroide hyperplasia, edema, vascular

congestion and macrophages with hemophagocytic activity (Figure 3A). Moreover EBV presence was tested with some EBER+ elements detection (Figure 3B). Immunohistochemistry for blasts and lymphoid infiltrated was negative. Cutaneous biopsy showed keratinocyte necrosis or basal vacuolization revealing skin biopsies revealed mild lymphocytic or histiocytic infiltration in the upper dermis (Figure 4). The search for EBV virus in cutaneous biopsy was negative.

After the diagnosis of hemophagocytic syndrome “EBV-related” infection, the patient started treatment according to HLH-94 protocol: dexamethasone and etoposide. An antiviral therapy was too performed with Aciclovir. No more cutaneous lesions appeared during the specific treatment but unfortunately the patient did not respond to the whole treatment and suddenly died after 15 days because of an acute respiratory failure likely due to pulmonary embolism. (Wells score = 6; genetic thrombophilia).

Discussion

Herpes virus family infections are frequently reported, particularly cytomegalovirus and EBV infections. EBV is considered the most common pathogen [2]. Infact EBV has been identified as the triggering virus in 74% of children in whom infectious agents were identified [3]. Most patients with EBV-associated HLH present a prolonged atypical infectious mononucleosis-like course, although some could develop a fatal disease rapidly.

Although EBV-associated HLH appears to be more common in the setting of reactivation, its occurrence in some immunocompetent children or young adults with classic mononucleosis suggests also an association with primary EBV infections [2,4].

In primary EBV infection, EBV virus and replicates primarily in CD21+ B cells. Occasionally, T cells are also infected. However, unlike in chronic persistent EBV infection, in which infected NK cells and CD4+ T cells are more frequent, in EBV-associated HLH, infected CD8+ T cells predominate [5].

The infection of the cytotoxic CD8+ T cells by EBV is believed to impair the proper function of these T cells, thus a setting up of cytotoxic pathway defection is the basis of HLH disease [6,7].

A lot of studies have shown that a significant number of patients with EBV-associated HLH have a clonal proliferation of T cells, particularly patients with recurrent EBV-disease. The clonal expansion is also indicated by the presence of homogeneous viral terminal repetitive sequences in both EBV-associated HLH and EBV-positive T-cell lymphoma. These findings shared by both T-cell lymphomas and EBV-associated HLH show a correlation between the 2 diseases [6-8].

Among all the viruses associated with HLH, EBV carries the worst prognosis, with a reported mortality ranging from 25% to 100% [3-7].

Conclusion

HLH associated with infection was originally described in patients under iatrogenic immunosuppression [9].

In this case, the bone marrow biopsy showed vascular congestion and macrophages with hemophagocytic activity. Moreover EBV presence was tested with some EBER + elements detection. (Figure 3A, 3B). This information makes the correlation between HLH and EBV stronger.

Hepatosplenomegaly, abdominal lymphadenopathy and icteric hepatitis might be caused by EBV-infection as well as HLH because they are features of both conditions.

Furthermore in skin lesions was found leukocytoclastic vasculitis. It is a form of small vessel vasculitis where neutrophils are predominant in the infiltrate and cellular fragments are present with nuclear debris [10].

It can be idiopathic or secondary to infections (mainly viral), drugs, connective tissue disease, malignancy and other diseases. Although skin biopsy did not show the presence of the EBV virus, the correlation between virus and skin lesions remains possible. Data in literature suggest that Epstein-Barr virus causes vasculitis of small vessels so the skin lesions can be indirectly EBV-associated.

Figures

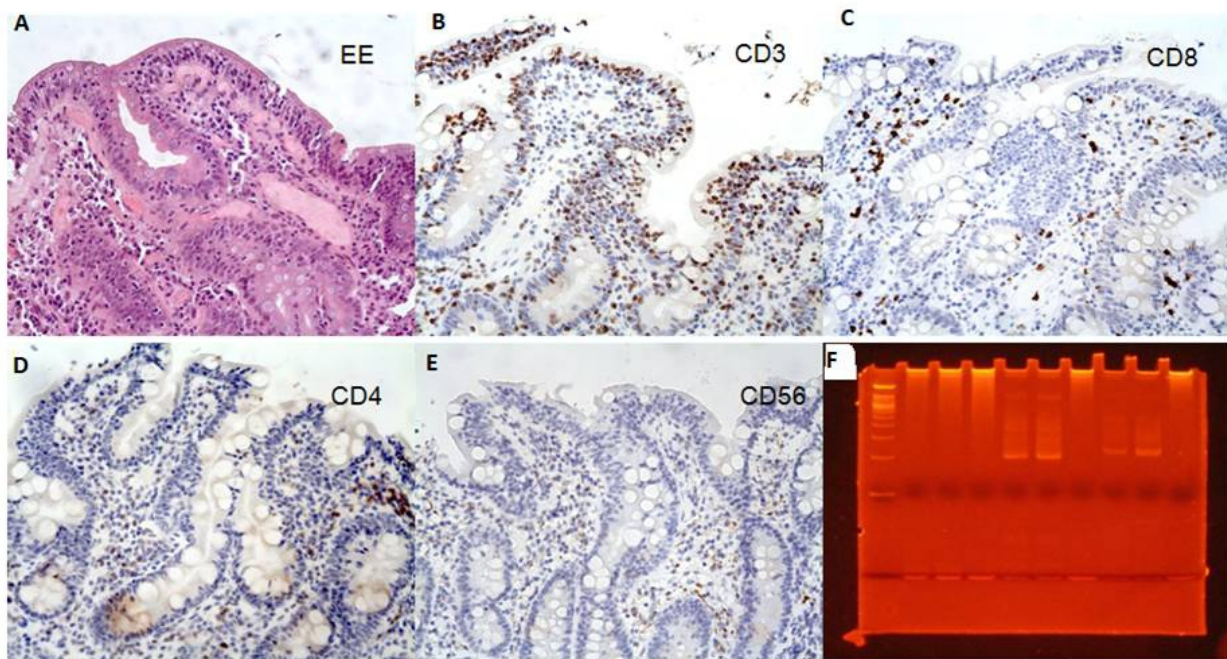


Figure 1: A-E: refractory celiac disease type 2; E: T cell receptor (TCR)

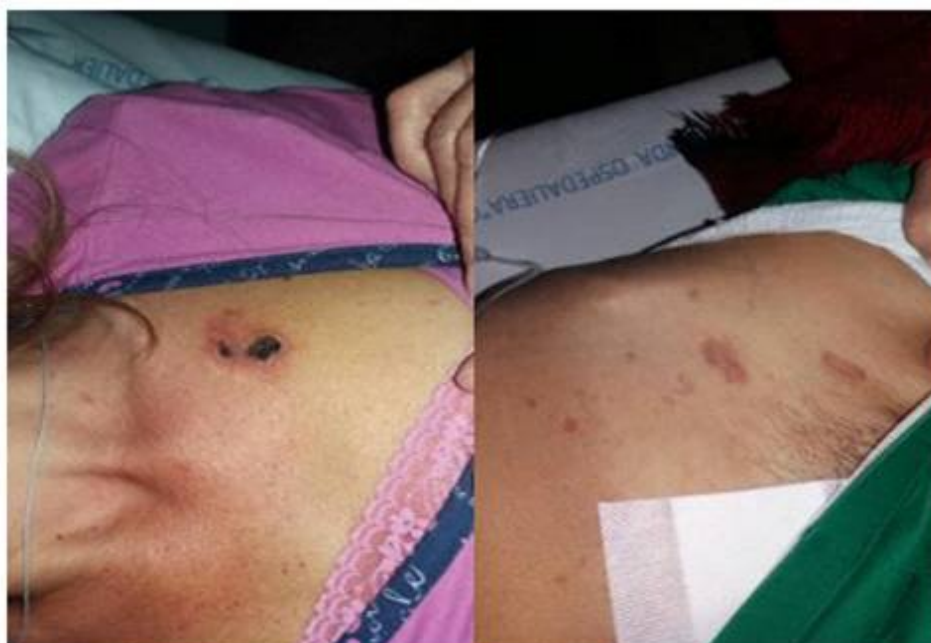

Figure 2: Skin lesions (cutaneous leukocytoclastic vasculitis)

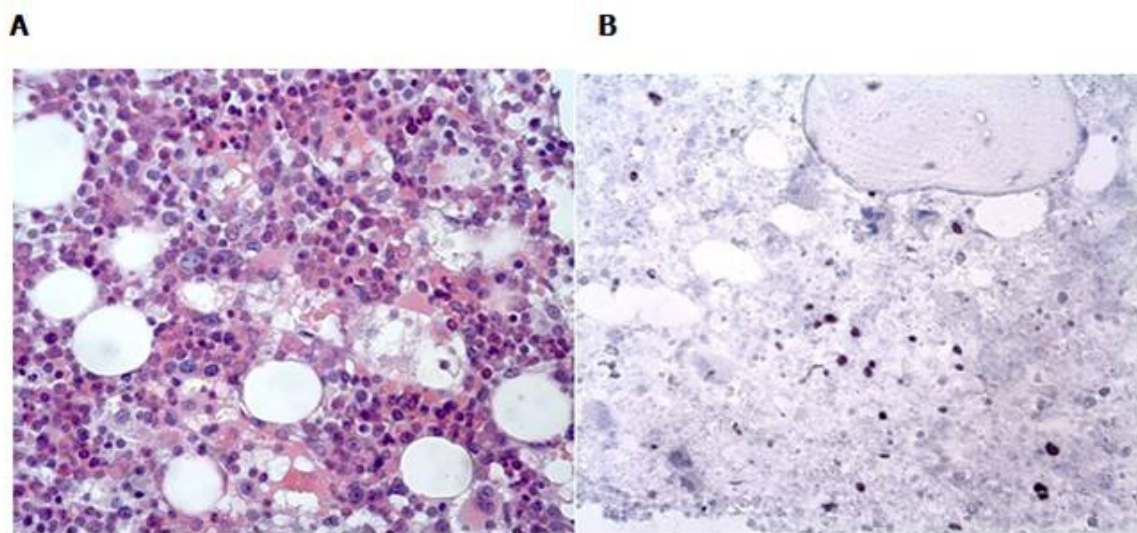


Figure 3: A: bone marrow biopsy, hematoxylin and eosin; B: EBER+ elements

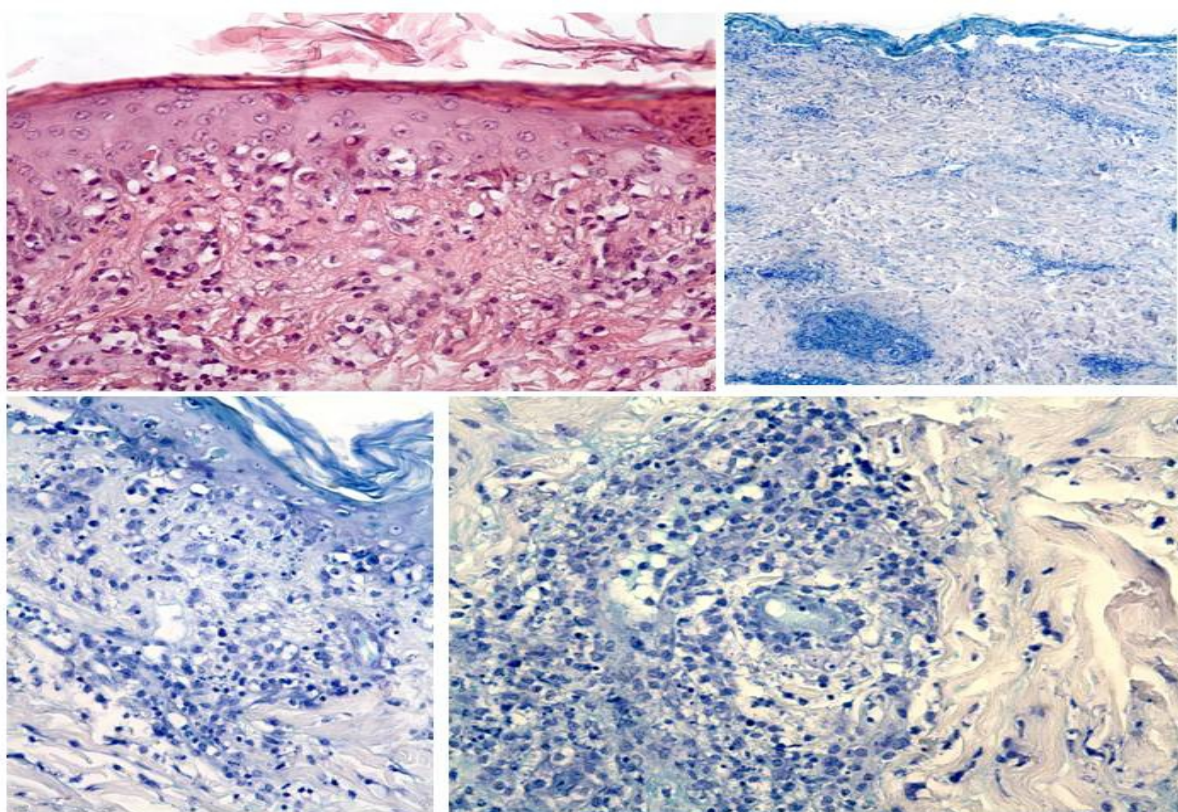


Figure 4: Cutaneous biopsy showed, EBER- elements

References

1. Allen M, De Fusco C, Legrand F, et al. Familial hemophagocytic lymphohistiocytosis: how late can the onset be? *Haematologica*. 2001;86:499-503.
2. Imashuku S. Clinical features and treatment strategies of Epstein-Barr virus-associated hemophagocytic lymphohistiocytosis. *Crit Rev Oncol Hematol*. 2002;44:259-272.
3. Janka G, Imashuku S, Elinder G, et al. Infection- and malignancy-associated hemophagocytic syndromes: secondary hemophagocytic lymphohistiocytosis. *Hematol Oncol Clin North Am*. 1998;12:435-444.

4. Imashuku S, Teramura T, Tauchi H, et al. Longitudinal follow-up of patients with Epstein-Barr virus-associated hemophagocytic lymphohistiocytosis. *Haematologica*. 2004;89:183-188.
5. Kasahara Y, Yachie A, Takei K, et al. Differential cellular targets of Epstein-Barr virus (EBV) infection between acute EBV-associated hemophagocytic lymphohistiocytosis and chronic active EBV infection. *Blood*. 2001;98:1882-1888.
6. Kawaguchi H, Miyashita T, Herbst H, et al. Epstein Barr virus-infected T lymphocytes in Epstein-Barr virus-associated hemophagocytic syndrome. *J Clin Invest*. 1993;92:1444-1450.
7. Kasahara Y, Yachie A. Cell type specific infection of Epstein-Barr virus (EBV) in EBV-associated hemophagocytic lymphohistiocytosis and chronic active EBV infection. *Crit Rev Oncol Hematol*. 2002;44:283-294.
8. Chan LC, Srivastava G, Pittaluga S, et al. Detection of clonal Epstein-Barr virus in malignant proliferation of peripheral blood CD3+ CD8+ T cells. *Leukemia*. 1992;6:952-956.
9. Karras A, Thervet E, Legendre C. Hemophagocytic syndrome in renal transplant recipients: report of 17 cases and review of literature. *Transplantation*. 2004;77:238-243.
10. Choucair J. Updates in the Diagnosis and Treatment of Vasculitis. *Infectious Cases Of Vasculitis*. 2013; 6:131-160.

Manuscript Information: Received: August 28, 2017; Accepted: November 02, 2017; Published: November 30, 2017

Authors Information: Mario Cottone*; Chiara Sapienza; Chiara Di Mitri; Aroldo Rizzo

Department of Internal Medicine, University of Palermo, Italy

Citation: Cottone M, Sapienza C, Di Mitri C, Rizzo A. Hemophagocytic syndrome EBV-related associated with leukocytoclastic vasculitis in a type-2 refractory celiac patient. *Open J Clin Med Case Rep*. 2017; 1337.

Copy right statement: Content published in the journal follows Creative Commons Attribution License (<http://creativecommons.org/licenses/by/4.0>). © Cottone M 2017

Journal: Open Journal of Clinical and Medical Case Reports is an international, open access, peer reviewed Journal focusing exclusively on case reports covering all areas of clinical & medical sciences.

Visit the journal website at www.jclinmedcasereports.com

For reprints and other information, contact editorial office at info@jclinmedcasereports.com