

Resolution of Pediatric Chronic Rhinitis using Biomimetic Oral Appliance Therapy: A Case Report

G. Dave Singh*; Soo-Chang Jung; Ravindra Chandrashekhar

***Prof. G. Dave Singh, DMD, PhD, DDSc**

BioModeling Solutions, Inc., 17933 NW Evergreen Parkway, Suite 280, Beaverton, OR 97006, USA

Tel: +1 971 302 2233, Fax: +1 866 201 3869; Email: drsingh@drdavesingh.com

Abstract

There are several methods of addressing chronic rhinitis (CR), including the use of various drugs and medications. However, other non-pharmacological methods of improving paranasal function have recently become available, such as balloon sinuplasty. This case report describes the resolution of CR in a 12 yr. old girl, using biomimetic oral appliance therapy (BOAT). In this case, treatment was completed over a period of 24 months. During this time, the patient showed less rhinorrhea, improved nasal breathing and regression of adenoidal hypertrophy. In addition, the patient's head posture, facial appearance and dental occlusion improved along with better sleep. Biomimetic oral appliance therapy may be beneficial in young patients with chronic rhinitis.

Keywords

Pediatric chronic rhinitis; Oral appliance therapy

Introduction

Common pathologies of the pediatric nasal and paranasal sinuses are typically inflammatory in nature. These diseases include acute and chronic rhinosinusitis, allergic rhinitis, and adenoidal hypertrophy. Chronic rhinosinusitis (CRS) can be defined as inflammation of the nasal and sinus mucosae for over 12 weeks. However, nasal obstruction can also cause disturbed facial growth. Therefore, descriptions of diseases of the nose and paranasal sinuses might also take midfacial growth into account [1]. Chronic rhinitis (CR) is a common disorder and allergic rhinitis (AR) is a risk factor for CR [2]. It is known that AR is an allergen-driven, mucosal, inflammatory disease, which is modulated by immunoglobulin E (IgE). Clinically, pediatric and adult patients with AR present with sneezing, rhinorrhea, nasal itching, nasal congestion and postnasal drainage. The most effective drugs for the treatment of AR are antihistamines and topical glucocorticoids, including intra-nasal formulations, such as azelastine hydrochloride and fluticasone propionate [3]. But, despite the availability of several pharmaceutical options, relief of symptoms such as nasal obstruction is often limited, and local adverse reactions are not uncommon [4]. However, recently, Hopkins et al. [5] reported that over 60% of patients treated with balloon sinuplasty note subjective improvement in AR symptoms. On the other hand, Saunders et al. [6] reported that specific structural changes can occur in CRS. For example, adults with CRS are more likely to develop it on the side with a more laterally-positioned uncinate process. Thus, structural modulation of the nasal cavity might be an alternative method of addressing various nasal

diseases, including CR. Therefore, a case report of biomimetic oral appliance therapy (BOAT) to address a pediatric case of CR is presented.

Case Report

This case report refers to a 12 yr. old Korean female (Fig. 1) whose parents gave informed consent and signed a patient release form, and her rights were protected by the Declaration of Helsinki (1964). She initially presented to our dental office where a medical screening evaluation revealed a history of CR and rhinorrhea. Further history-taking discovered a history of mouth breathing; chronic, fever-like symptoms, and poor academic performance in school due to “brain fog”.

Examination and Assessment

Physical and radiographic evaluations were undertaken, including facial and intra-oral photography, which revealed the following findings;

Long face phenotype (Fig. 1)

Forward head posture (Fig. 2) with counterclockwise rotation of the head (Fig. 2).

Anterior crowding of the maxillary teeth with mild torus palatinus and bilateral torus mandibularis (Figs. 3a and 3b).

Nasal obstruction (Fig. 4).

Adenoidal hypertrophy (Fig. 5).

Diagnosis

The working and differential diagnoses in this case included;

Adenoid facies

Class I malocclusion with anterior crossbite

Maxillary hypoplasia

Sleep bruxism

Obstructive sleep apnea with hypersomnia

Therefore, a comprehensive treatment plan was formulated as noted below.

Treatment

The patient was advised to improve her sleep hygiene, including going to bed by 10pm. She was also instructed on keeping her lips closed as much as possible, particularly while at rest. In addition, nutritional counseling was implemented. Next, a biomimetic, upper appliance was prescribed (DNA appliance®, Fig. 6). This appliance system is designed to correct maxillo-mandibular development in both children and adults [7-13]. The patient was instructed to wear the device during the late afternoon after school, during the early evening and at nighttime during sleep (for approx. 12-16hrs. in total), but not during the day and not while eating, partly in line with the circadian rhythm of tooth eruption [14]. The patient reported for review every 4 weeks, approximately. At each monthly follow-up, examination for the progress of midfacial development was recorded. Adjustments to the device were also performed to optimize its efficacy. Only gentle pressures were transmitted to the teeth, and the functionality of the device was checked with the subject activating a mild force on biting. The patient was encouraged to maintain the protocol until the end of treatment.

Results

After 18 months of active treatment, the patient reported a resolution of CR and rhinorrhea, better nasal breathing, better sleep and no more “brain fog”. In addition, she noticed an improved facial appearance and smile esthetics (Fig. 7). Therefore, after a further 12 months we found;

Improved facial phenotype (Fig. 7)

Improved head posture (Fig. 8)

Resolution of malocclusion and anterior crossbite (Figs. 9a and 9b)

Decreased nasal obstruction (Fig. 10), suggesting an improved upper airway.

Resolution of adenoidal hypertrophy (Fig. 11), suggesting an improved upper airway.

Discussion

Studies evaluating 2D cephalographs for the effects of rapid maxillary expansion (RPE) in actively-growing children report both a widening of the maxilla and the base of the nose, so that the nasal cavities are larger at the end of treatment [15]. However, during RPE the sutures that unite the two halves of the midface are split apart, and the process of bone fracture healing ensues. In contrast, the BOAT protocol used in this study maintained sutural integrity, whilst simultaneously producing craniofacial enhancement (Figs. 7-8). It is likely that BOAT promotes circum-maxillary sutural remodeling (induced midfacial morphogenesis) by inducing a biomolecular response that deploys the same physiologic mechanisms used in passively-growing adults, undergoing an osteogenetic-orthodontic protocol [16]. In osteogenetic-orthodontics, we suggest that the mechanisms of sutural homeostasis are evoked that produce an enhanced midfacial complex as evidenced by the growth of the nasal cavity in adults [17]. The changes in facial growth and development that BOAT putatively induces is a phenomenon that is in line with the spatial matrix hypothesis [18]. These changes in the functional space of the nasal cavity include dento-alveolar and midpalatal responses associated with a wider maxillary arch and a broader smile, which also enhances facial esthetics. Therefore, improved facial form (esthetics) and functional spaces (such as the nasal airway) are evident (Figs. 7-8 and 10-11). Thus, BOAT may be an alternative treatment choice for pediatric cases of CR. However, Evcimik et al. [19] noted that adenoidal hypertrophy may be associated with comorbid conditions, including sleep apnea and chronic sinusitis. Furthermore, these conditions are more common among children with allergic diseases. Han et al. [20] identified novel risk factors for the development of allergic rhinitis in Korean schoolchildren. On the other hand, Stenner [1] suggested that adenoids might act as a reservoir for recurrent infections of the nose and nasal sinus, and nearly 70% of children with rhinosinusitis benefit from adenoidectomy. Not surprisingly, Warman et al. [2] reported improvements in rhinitis secondary to adenoidectomy in children. In our study, we noted regression of adenoidal hypertrophy (Fig. 11) and this finding may have helped in the resolution of CR in this case. Therefore, further research is required to ascertain the relationship between CR and adenoidal hypertrophy, including the mechanism by which adenoidal hypertrophy is resolved.

Conclusion

Biomimetic oral appliance therapy may be considered in pediatric patients with chronic rhinitis.

Acknowledgements

We would like to thank Steven Y. Park, MD, Department of Otorhinolaryngology-Head and Neck Surgery, Montefiore Medical Center, Albert Einstein College of Medicine, New York for his guidance in the preparation of this manuscript.

Figures



Figure 1



Figure 7

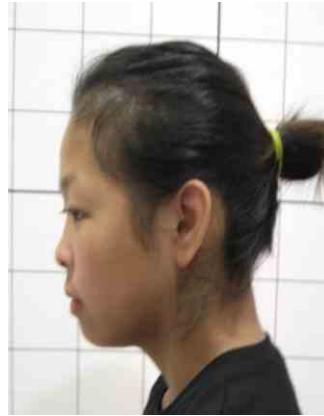

Figure 2



Figure 8

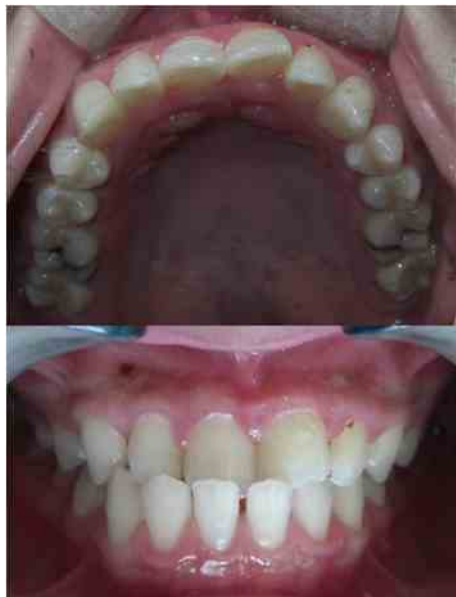

Figure 3a & 3b

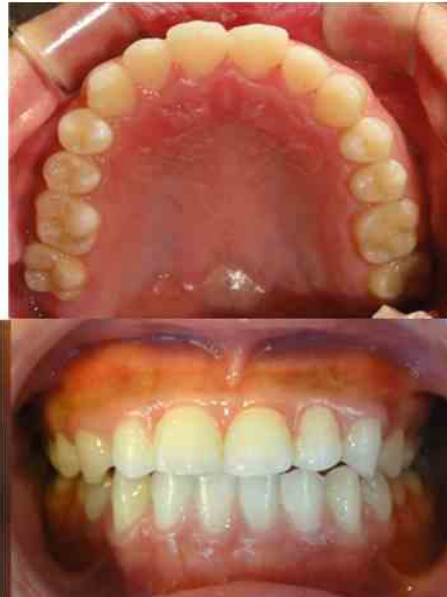

Figure 9a & 9b

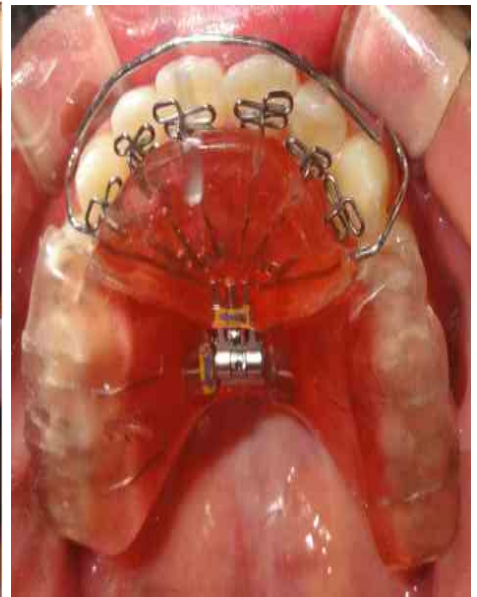


Figure 6

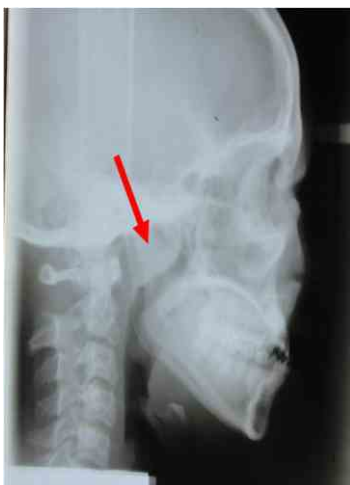

Figure 5

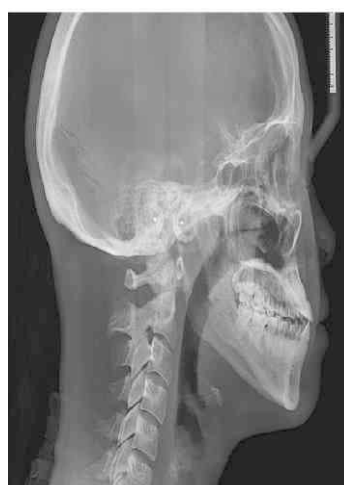

Figure 11

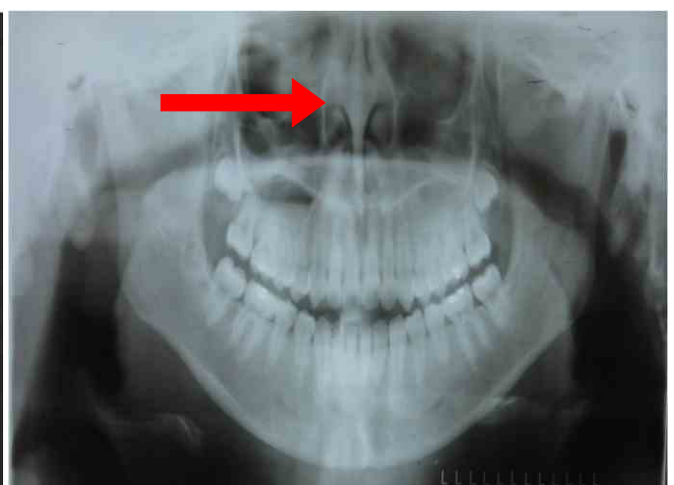


Figure 4

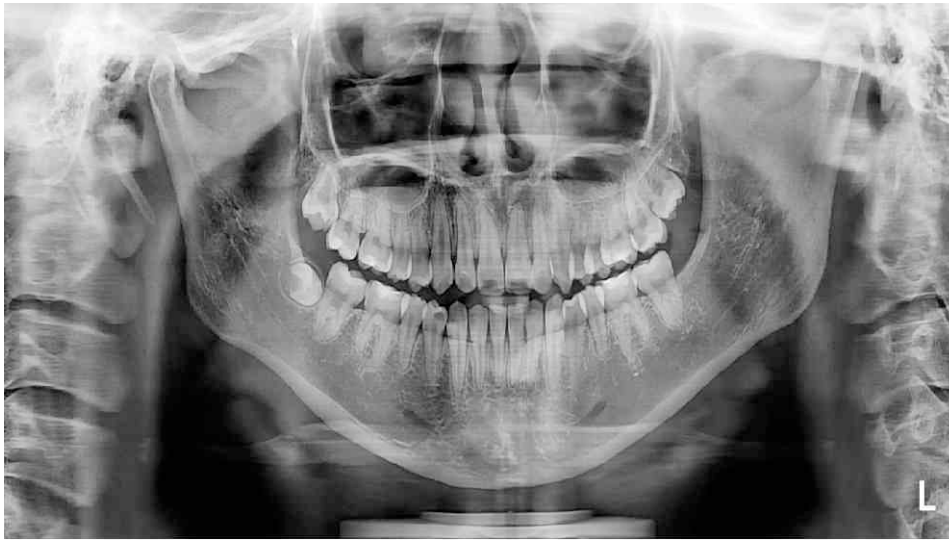

Figure 10

References

1. Stenner M, Rudack C. Diseases of the nose and paranasal sinuses in child. *GMS Curr Top Otorhinolaryngol Head Neck Surg.* 2014;13:Doc10. doi: 10.3205/cto000113. eCollection 2014.
2. Waran M, Granot E, Halperin D. Improvement in allergic and nonallergic rhinitis: A secondary benefit of adenoidectomy in children. *Ear Nose Throat J.* 2015; 94(6):220-7.
3. Ridolo E, Montagni M, Melli V, Bonzano L, Incorvaia C, Canonica GW. A role for the intranasal formulation of azelastine hydrochloride/fluticasone propionate in the treatment of allergic rhinitis. *Ther Deliv.* 2015; 1-7. [Epub ahead of print]
4. Passali D, Passali FM, Loglisci M, Cambi J, Bellussi LM. Efficacy and safety of a medical device in reducing nasal obstruction in allergic children. *Minerva Pediatr.* 2015; 67(3):239-43.
5. Hopkins C, Noon E, Bray D, Roberts D. Balloon sinuplasty: our first year. *J Laryngol Otol.* 2011;125(1):43-52. doi: 10.1017/S0022215110001520. Epub 2010 Aug 24.
6. Saunders NC, Birchall MA, Armstrong SJ, Killingback N, Singh GD. Morphometry of paranasal sinus anatomy in chronic rhinosinusitis: a pilot study. *Arch Otolaryngol Head Neck Surg.* 1998;124(6):656-8.
7. Singh GD, Lipka G. Case Report: Introducing the wireframe DNA appliance™. *J Am Acad Gnathol Orthop.* 2009;26:8-11.
8. Singh GD, Wendling S, Chandrashekhar R. Midfacial development in adult obstructive sleep apnea. *Dent Today* 2011;30:124-7.
9. Singh GD, Utama J. Effect of the DNA appliance™ on migraine headache: Case report. *Int J Orthod.* 2013;24:45-9.
10. Singh GD, Cress SE. Craniofacial enhancement using a biomimetic oral appliance: Case Report. *Dent Today* 2013;329:92-4.
11. Singh GD and Callister JD. Use of a maxillary oral appliance for the resolution of obstructive sleep apnea. *J Cranio Sleep Prac.* 2013;31:171-9.
12. Harris WG, Singh GD. Resolution of 'gummy smile' and anterior open bite using the DNA appliance™: Case Report. *J Amer Orthod Soc.* 2013:30-4.
13. Liao F, Singh GD. Resolution of Sleep Bruxism using Biomimetic Oral Appliance Therapy: A Case Report. *J Sleep Disord Ther* 2015;4:204. doi:10.4172/2167-0277.1000204.

14. Proffit WR, Frazier-Bowers SA. Mechanism and control of tooth eruption: overview and clinical implications. *Orthod Craniofac Res*. 2009;12:59-66.
15. Franchi L, Baccetti T, Cameron C, Kucipal E, McNamara JA. Thin-plate spline analysis of short and long term effects of rapid maxillary expansion. *Euro J Orthod*. 2002; 24: 143-50.
16. Singh GD, Heit T, Preble D. Changes in 3D midfacial parameters after biomimetic oral appliance therapy in adults. *J Ind Orthod Soc*. 2014;8(2):104-8.
17. Singh GD, Heit T, Preble D, Chandrashekhar R. Changes in 3D nasal cavity volume after biomimetic oral appliance therapy in adults. *Cranio* 2016;34(1):6-12. doi: 10.1179/2151090315Y.0000000001. Epub 2015 Jan 27.
18. Singh GD. On Growth and Treatment: the Spatial Matrix hypothesis. In: *Growth and treatment: A meeting of the minds*. McNamara JA Jr (ed.) Vol 41, Craniofacial Growth Series, Ann Arbor, USA, 2004, 197-239.
19. Evcimik MF, Dogru M, Cirik AA, Nepesov MI. Adenoid hypertrophy in children with allergic disease and influential factors. *Int J Pediatr Otorhinolaryngol*. 2015;79(5):694-7. doi: 10.1016/j.ijporl.2015.02.017. Epub 2015 Feb 25.
20. Han DH, Ahn JC, Mun SJ, Park SK, Oh SY, Rhee CS. Novel risk factors for allergic rhinitis in Korean elementary school children: ARCO-kids Phase II in a community. *Allergy Asthma Immunol Res*. 2015;7(3):234-40. doi: 10.4168/aair.2015.7.3.234. Epub 2015 Jan 23.

Manuscript Information: Received: November 18, 2015; Accepted: February 19, 2016; Published: February 23, 2016

Authors Information: G. Dave Singh^{*1}; Soo-Chang Jung²; Ravindra Chandrashekhar³

¹BioModeling Solutions, Inc, Beaverton, OR 97006, USA

²Oklahoma Natural Dental Clinic, Seoul, South Korea

³PO Box 8745, Tyler, TX 75711, USA

Citation: Singh GD, Jung SC, Chandrashekhar R. Resolution of pediatric chronic rhinitis using biomimetic oral appliance therapy: a case report. *Open J Clin Med Case Rep*. 2016; 1082

Copy right Statement: Content published in the journal follows Creative Commons Attribution License (<http://creativecommons.org/licenses/by/4.0>). © Singh GD 2016

Journal: Open Journal of Clinical and Medical Case Reports is an international, open access, peer reviewed Journal focusing exclusively on case reports covering all areas of clinical & medical sciences.

Visit the journal website at www.jclinmedcasereports.com

For reprints & other information, contact editorial office at info@jclinmedcasereports.com